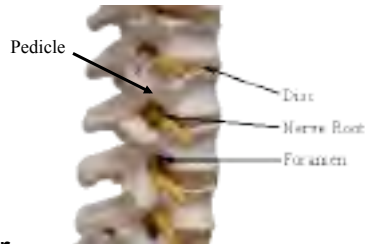

Percutaneous Vertebroplasty

- Injection of cement into vertebral bodies using large needle inserted through pedicle
- Indications include fractures, osteoporosis, tumors
- Often relieves pain
- Typically performed freehand under fluoroscopic x-ray guidance



Note on sources:

- [1] These slides are adapted from a 2000 powerpoint presentation provided by Dr. John Mathis, MD
 - [2] The instructional video is from a CD titled "Vertebroplasty", from Drs. G. Zoarsky and A. O. Ortiz, 2000
- The cdroms are on reserve in the library




Copyright © CISST ERC, 2006

NSF Engineering Research Center for Computer Integrated Surgical Systems and Technology



History

- **Bone augmentation with acrylic cement**
 - Bone cancer (Vidal, 1969)
 - Hip replacement (Chamley, 1970)
- **Percutaneous vertebroplasty**
 - First case: Amiens, France, (Gailbert & Deramond, 1984)
 - 50 year-old female with neck pain due to a cervical (C2) hemangioma



Source: J. Mathis

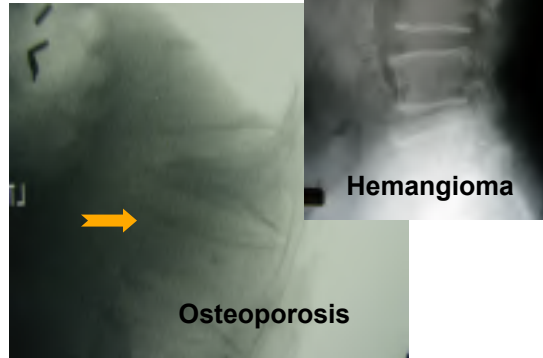
Copyright © CISST ERC, 2006

NSF Engineering Research Center for Computer Integrated Surgical Systems and Technology



Vertebral body compression fractures

- Osteoporosis
 - women:men = 2:1
 - 26% of women > 50 years
- Primary neoplasms
 - Hemangiomas
 - Myelomas
- Secondary neoplasms
 - Metastases
 - Lymphomas



Source: J. Mathis

Copyright © CISST ERC, 2006

NSF Engineering Research Center for Computer Integrated Surgical Systems and Technology



Economics & Patient Impact

- 1.5 million osteoporotic fractures annually in the United States
 - 500,000-700,000 vertebral fractures
 - In 1995, osteoporotic fractures accounted for
 - 2.5 million physician visits
 - 432,000 hospital admissions
 - 180,000 thousand nursing home admissions
 - \$13.5 billion in direct medical expenses
- Pain
 - Diminished mobility
 - Loss of employment
 - Narcotic addiction
 - Urinary retention
 - Ileus
 - Insomnia
 - Depression
 - Kyphosis
 - Spinal cord compression

Source: J. Mathis

Copyright © CISST ERC, 2006

NSF Engineering Research Center for Computer Integrated Surgical Systems and Technology



Osteoporotic Compression Fractures: Traditional Management

- Analgesics
 - Temporary
 - Side effects
- Bed rest
 - Deep venous thrombosis
 - pneumonia
- Immobilization
 - Variable success
 - May cause further demineralization
- Surgery
 - High failure rate

Source: J. Mathis

Copyright © CISST ERC, 2006

NSF Engineering Research Center for Computer Integrated Surgical Systems and Technology



Benefits & Efficacy of Vertebroplasty

- Pain relief is quick and complete
 - Various explanations as to why it works
- Patients able to stand and walk within first 24 hours
- Osteoporotic compression fractures
 - 85-90% of patients experience dramatic or complete relief of pain within several to 72 hours
- Neoplastic compression fractures
 - 60-70% of patients experience marked reduction in narcotic requirements or complete pain relief

Source: J. Mathis

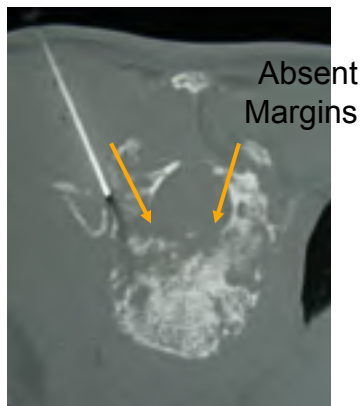
Copyright © CISST ERC, 2006

NSF Engineering Research Center for Computer Integrated Surgical Systems and Technology



Indications

- Osteoporosis
 - Relieve pain
 - Stabilize spine
- Tumors
 - Relieve pain
 - Biopsy opportunity
- Cautions:
 - Pain relief for tumors may be less than for osteoporosis
 - Risk of cement extraversion if cortex is too thin



Source: J. Mathis

Copyright © CISST ERC, 2006

NSF Engineering Research Center for Computer Integrated Surgical Systems and Technology



Patient Selection

- Patients who are less likely to respond
 - Fracture present for >1 year
 - Other causes for back pain are present
 - Disc herniation, spinal stenosis, facet or sacroiliac joint disease...
 - Radicular pain related to disc herniation
- Acute or subacute compression fracture(s) on plain radiographs or MRI
- Pain corresponding to level of the fracture



Video: Zoarsky & Ortiz

Source: J. Mathis

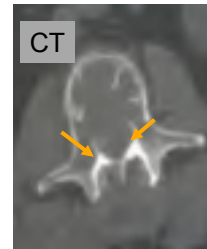
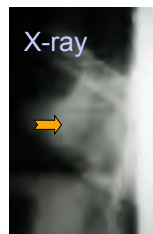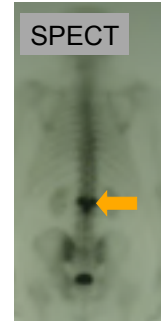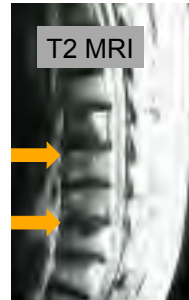
Copyright © CISST ERC, 2006

NSF Engineering Research Center for Computer Integrated Surgical Systems and Technology



Pre-procedure Imaging

- Plain radiographs
 - Compare with prior studies
- MRI
 - Assess for vertebral body marrow edema
 - Exclude stenosis due to disc and/or facet disease
- SPECT
 - (metastatic cancer workup)



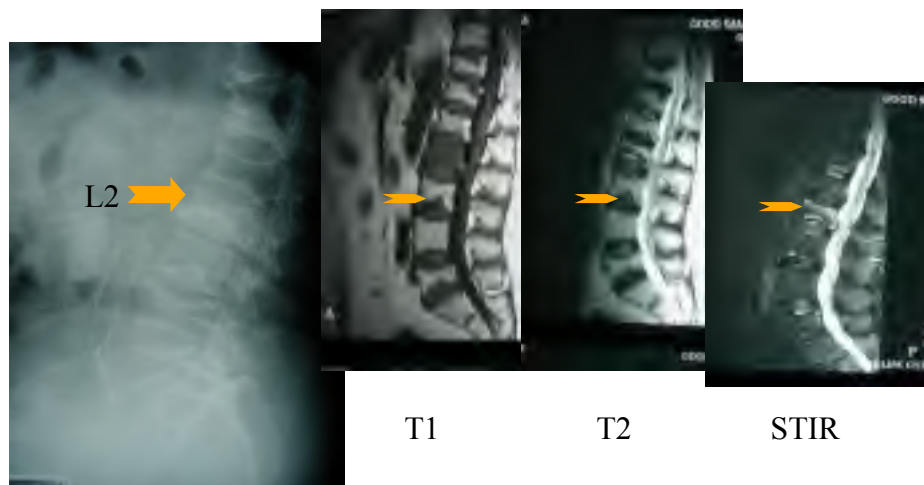
Source: J. Mathis

Copyright © CISST ERC, 2006

NSF Engineering Research Center for Computer Integrated Surgical Systems and Technology



L-2 Compression Fracture



Source: J. Mathis

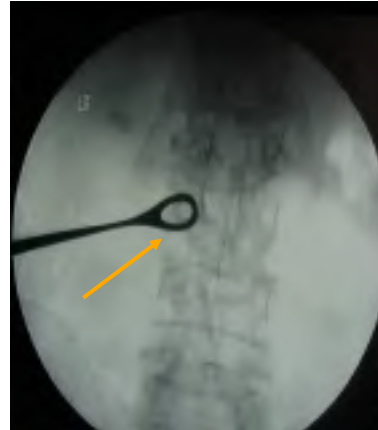Copyright © CISST ERC, 2006

NSF Engineering Research Center for Computer Integrated Surgical Systems and Technology



Pre-procedure Consultation

- Fluoroscopic examination
 - Determine correspondence between painful sites and levels of vertebral body compression
- Informed consent process



Source: J. Mathis

Video: Zoarsky & Ortiz

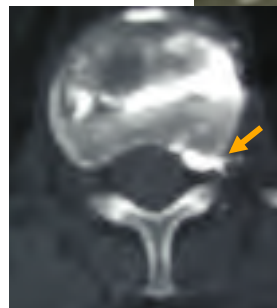
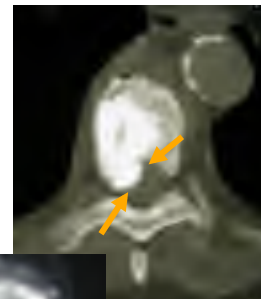Copyright © CISST ERC, 2006

NSF Engineering Research Center for Computer Integrated Surgical Systems and Technology



Complications

- Overall incidence
 - minor <3%; major <<1%
 - metastatic cases 10%
- Spine / nerve root injury <1%
- Hemorrhage (rare)
- Infection (rare)
- Fracture of lamina or pedicle
- Cement extraversion
 - Osteoporosis - 1-2%
 - Neoplasms - 5-10%
- Increased pain 1-2%
- Death



Source: J. Mathis

Copyright © CISST ERC, 2006

NSF Engineering Research Center for Computer Integrated Surgical Systems and Technology



Imaging Guidance

- High quality fluoroscopy
 - Biplane
 - Single plane
 - C-arm
- Computed tomography
 - CT and fluoroscopy



Source: J. Mathis

Copyright © CISST ERC, 2006

NSF Engineering Research Center for Computer Integrated Surgical Systems and Technology



Procedure

1. Localize symptomatic vertebral body level(s) prior to prepping the skin
2. Choose approach
 - Posterolateral (thoracic or lumbar spine)
 - Transpedicular – most common route
 - Parapedicular
 - Anterolateral (cervical spine)
3. Anesthetize skin and subcutaneous tissues down to the level of the periosteum
4. Cut small skin incision with scalpel
5. Insert needle
6. Inject small amount of contrast for assessment (optional)
7. Mix & Inject cement

Source: J. Mathis

Copyright © CISST ERC, 2006

NSF Engineering Research Center for Computer Integrated Surgical Systems and Technology



Procedure: Instructional Video

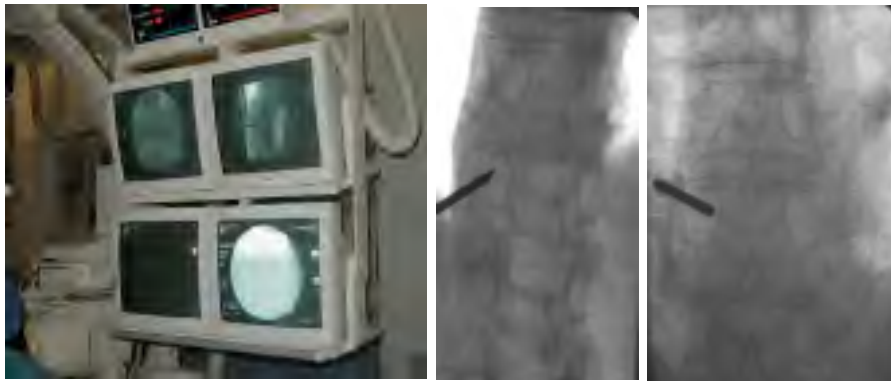

Copyright © CISST ERC, 2006

NSF Engineering Research Center for Computer Integrated Surgical Systems and Technology



Procedure: Needle Insertion with image guidance



Source: J. Mathis

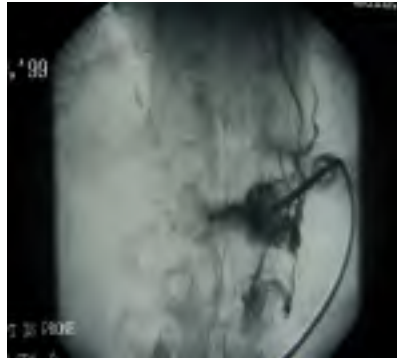Copyright © CISST ERC, 2006

NSF Engineering Research Center for Computer Integrated Surgical Systems and Technology



Procedure: Contrast injection

- Performed through bone needle
- Requires injection of small volume of dilute low osmolar nonionic contrast agent (make sure patient is not allergic)
- Optional procedure
 - May predict pattern of the cement injection
 - Will identify a direct venous communication
 - May interfere with visualization of opacified cement
 - Must wash out contrast agent with sterile saline



Source: J. Mathis

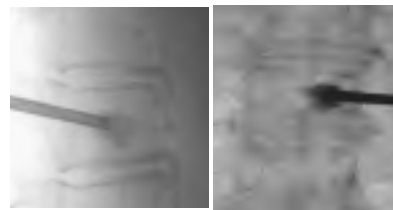
Copyright © CISST ERC, 2006

NSF Engineering Research Center for Computer Integrated Surgical Systems and Technology



Procedure: Prepare and inject cement

- Various manufacturers
- Polymer powder
- Liquid monomer
- Opacifying agent
 - Barium sulfate; tungsten powder; tantalum
- Optional antibiotic additive
- Limited working time (~10 mins)
- Various injection systems
- Inject into vertebral body under real time fluoroscopic monitoring



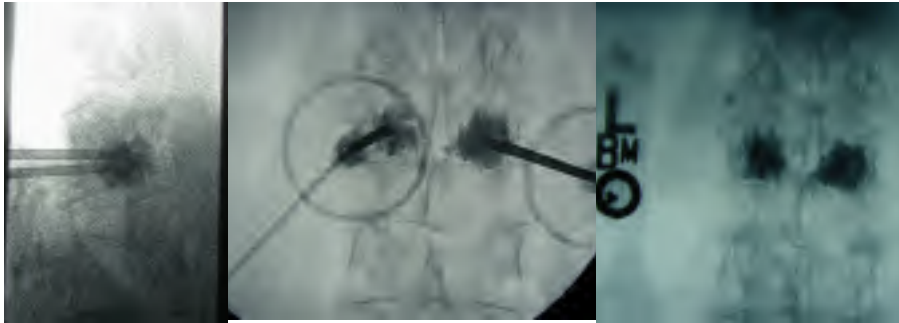
Source: J. Mathis

Copyright © CISST ERC, 2006

NSF Engineering Research Center for Computer Integrated Surgical Systems and Technology



Case #1: 74 Y.O. F With Osteoporosis And Painful L3 Fracture




Source: J. Mathis

Copyright © CISST ERC, 2006

NSF Engineering Research Center for Computer Integrated Surgical Systems and Technology



Case #2: 80 Y.O. F Fell From Bed



- Severe, 10/10, non-radiating upper back pain
- Exquisite tenderness to palpation
- No relief with analgesics or bed rest
- Constipation

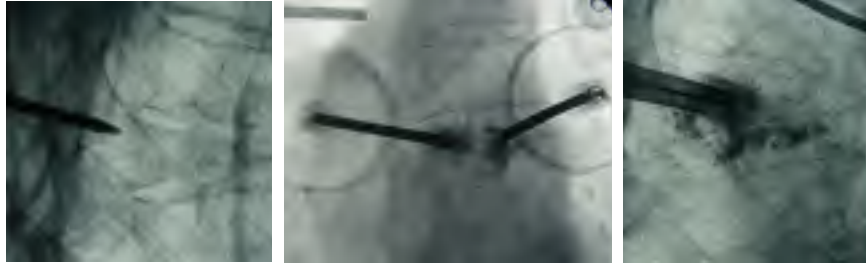Source: J. Mathis

Copyright © CISST ERC, 2006

NSF Engineering Research Center for Computer Integrated Surgical Systems and Technology



Case #2: 80 Y.O. F Fell From Bed



Complete symptomatic relief in 24 hours

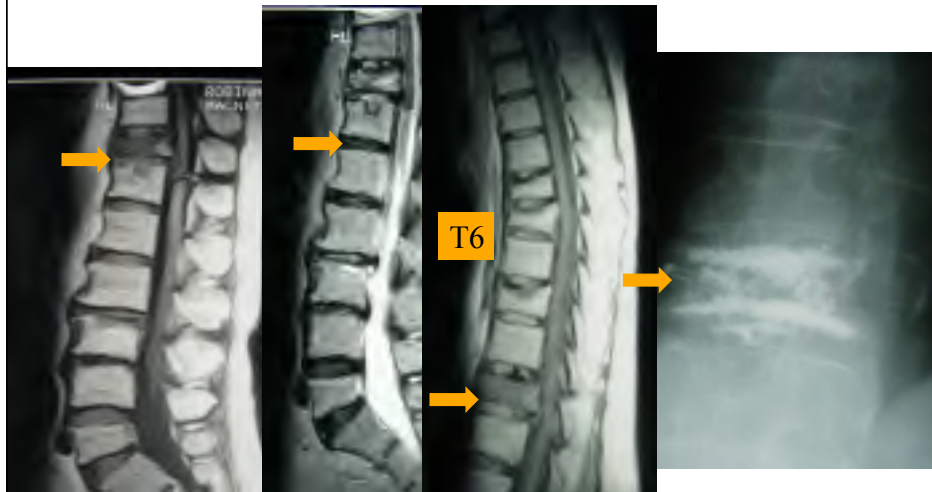
Source: J. Mathis

Copyright © CISST ERC, 2006

NSF Engineering Research Center for Computer Integrated Surgical Systems and Technology



Case #3: 75 Y.O. F With Acute Non-traumatic Low Back Pain



Painful T11 Compression Fracture

T11 Vertebroplasty

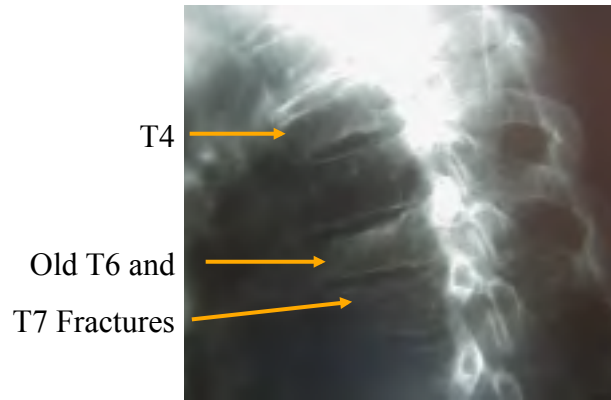
Source: J. Mathis

Copyright © CISST ERC, 2006

NSF Engineering Research Center for Computer Integrated Surgical Systems and Technology



Case #3: 5 Months Later Presents With Acute Upper Thoracic Pain



- A new compression fracture is seen at T4
- Compare to the previous MRI study

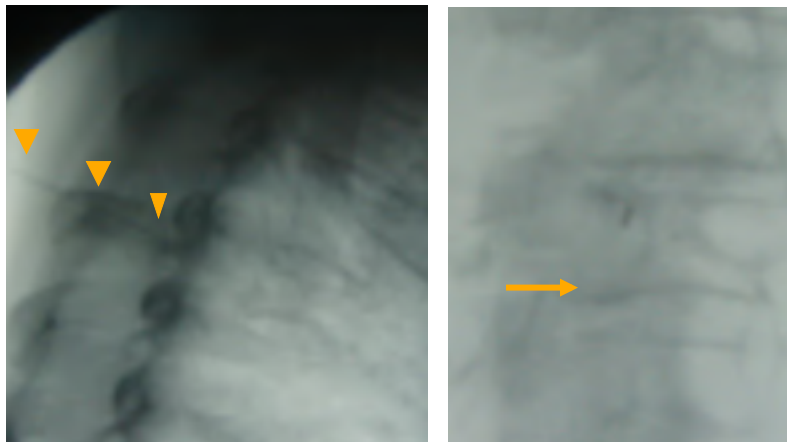
Source: J. Mathis

Copyright © CISST ERC, 2006

NSF Engineering Research Center for Computer Integrated Surgical Systems and Technology



Case #3: Needle Localization and Anesthesia At The T4 Level




Source: J. Mathis

Copyright © CISST ERC, 2006

NSF Engineering Research Center for Computer Integrated Surgical Systems and Technology



Case #3: Needle Insertion Through Left T4 Pedicle



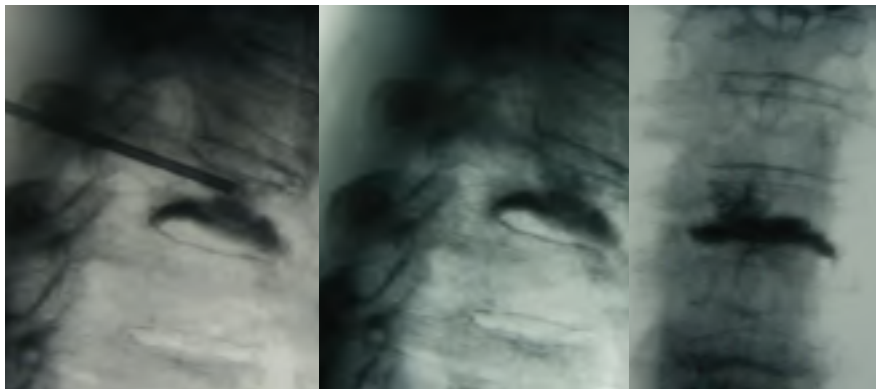
Source: J. Mathis

Copyright © CISST ERC, 2006

NSF Engineering Research Center for Computer Integrated Surgical Systems and Technology



Case #3: T4 Vertebroplasty



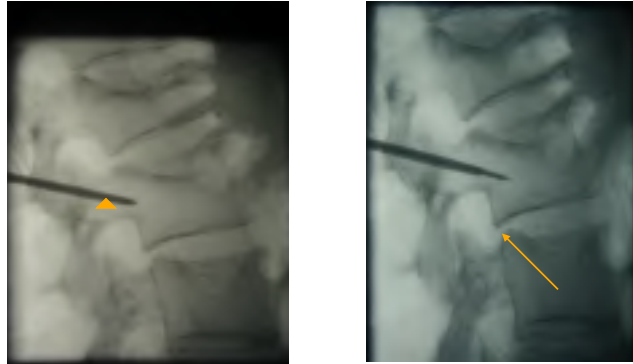
Source: J. Mathis

Copyright © CISST ERC, 2006

NSF Engineering Research Center for Computer Integrated Surgical Systems and Technology



Case #4: 64 Y.O. M H/O Leukemia With Acute Low Back Pain



- 3 Lumbar compression deformities
- Bone biopsy (arrow) performed through cannula (arrowhead) of the bone needle

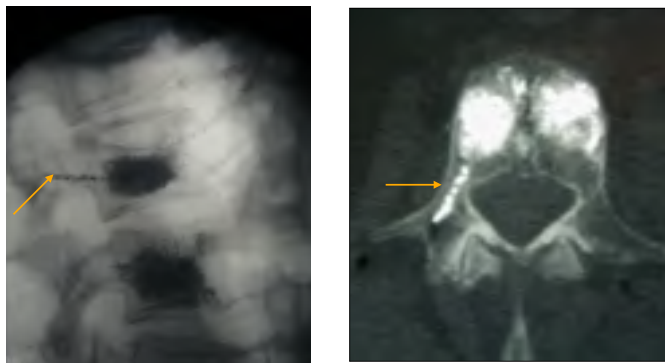
Source: J. Mathis

Copyright © CISST ERC, 2006

NSF Engineering Research Center for Computer Integrated Surgical Systems and Technology



Case #4: Vertebroplasty of L2 and L3



- CT scan obtained through L2 level shows cement within the vertebral body and right pedicle
- Patient experienced partial relief of his pain symptoms

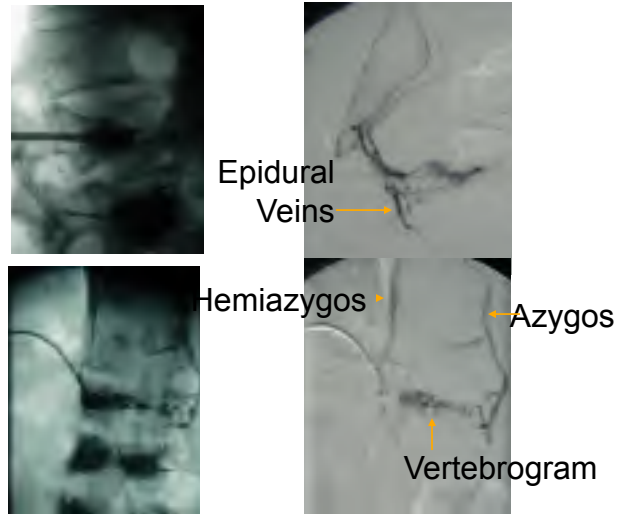
Source: J. Mathis

Copyright © CISST ERC, 2006

NSF Engineering Research Center for Computer Integrated Surgical Systems and Technology



Case #4: Venogram At L1 Shows Azygos and Epidural Veins



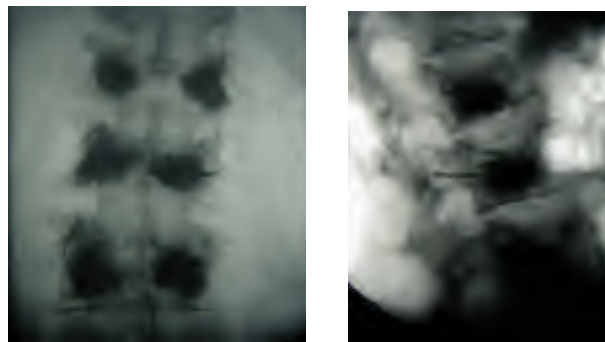
Source: J. Mathis

Copyright © CISST ERC, 2006

NSF Engineering Research Center for Computer Integrated Surgical Systems and Technology



Case #4: L1 Vertebroplasty Second Session



- Patient experienced complete pain relief
- Biopsy results showed no recurrence of neoplasm

Source: J. Mathis

Copyright © CISST ERC, 2006

NSF Engineering Research Center for Computer Integrated Surgical Systems and Technology



Results (J. Mathis)

- Recent small series have demonstrated the utility of vertebroplasty in relieving the pain that is associated with pathologic compression fractures
- Increased patient mobility
- Diminished requirement for analgesics

Jensen ME, Evans AE, Mathis JM, Kallmes DF, Cloft HJ, Dion JE. Percutaneous polymethylmethacrylate vertebroplasty in the treatment of osteoporotic vertebral body compression fractures: technical aspects. *AJNR* 1997; 18:1997-1904

Source: J. Mathis

Copyright © CISST ERC, 2006

NSF Engineering Research Center for Computer Integrated Surgical Systems and Technology



Conclusions (J. Mathis)

- In experienced hands and with appropriate patient selection, vertebroplasty is a safe and efficacious procedure for the treatment of pain and disability associated with osteoporotic compression fractures
- The procedure has a low complication rate and a very high success rate
- Vertebroplasty is a palliative procedure and does not correct the underlying cause of the vertebral fracture
- Medical management of osteoporosis or malignancy must therefore be initiated and continued

Source: J. Mathis

Copyright © CISST ERC, 2006

NSF Engineering Research Center for Computer Integrated Surgical Systems and Technology

