

Advanced Bionics Thin Lateral and Helix II Electrodes: A Temporal Bone Study

Charles G. Wright, PhD; Peter S. Roland, MD; Janusz Kuzma, ME

Objective: This study was performed to evaluate the insertional properties of two cochlear implant electrodes recently developed by Advanced Bionics Corporation. **Study Design:** Anatomic study using human cadaveric temporal bones. **Methods:** The electrode prototypes we tested are the Thin Lateral and Helix II arrays, which incorporate features designed to minimize insertional trauma. A total of eight electrodes (4 of each prototype) were evaluated after insertion into freshly fixed temporal bones. The electrodes were inserted by way of standard cochleostomies, and the specimens were subsequently dissected to assess electrode position, insertion depth, and intracochlear trauma. **Results:** Quantitative data regarding insertion depths and contact distances from the modiolus are presented for all electrodes tested. The mean insertion depths were 368° for the Thin Lateral electrodes, which are designed to approximate the lateral cochlear wall, and 436° for the Helix II electrodes, which occupy a more medial position in the scala tympani. No evidence of insertional trauma was observed with either electrode. The ease of insertion and absence of trauma were confirmed during additional trials in which electrode behavior was directly observed during insertion into previously opened cochleas. **Conclusion:** Both electrodes performed favorably in our human temporal bone trials, and both arrays appear promising for clinical use, especially in patients with residual hearing in whom atraumatic insertion is an important objective. **Key Words:** Cochlear implant electrodes, human temporal bones, microdissection.

Laryngoscope, 115:2041–2045, 2005

INTRODUCTION

Cochlear implant electrode technology has evolved rapidly in recent years with an emphasis on design fea-

tures intended to ensure optimal electrical stimulation and to minimize insertional trauma. Reduction or elimination of insertional trauma is clearly an important factor for hearing conservation in implant recipients who retain significant levels of residual auditory function. This is particularly true for those patients who may benefit from newly emerging stimulus strategies that use a combination of electrical and acoustic stimulation.¹

Advanced Bionics Corporation (Sylmar, CA) has developed two new electrode prototypes that incorporate design features intended to facilitate atraumatic insertion. The first of these, the Thin Lateral electrode, is engineered to be positioned against the lateral wall of the cochlea immediately beneath the basilar membrane, whereas the other electrode, the Helix II, is designed to occupy the middle portion of the scala tympani, closer to the modiolus. Both arrays use 16 active contacts spaced approximately 0.9 mm apart.

Cochlear microdissection was used in this study to evaluate the insertional properties of Thin Lateral and Helix II electrodes that were placed in human cadaveric temporal bones. The microdissection method for study of the human inner ear permits direct, three-dimensional visualization of the entire length of an electrode array inside the cochlea, allowing detailed documentation of electrode position and assessment of any trauma that may have occurred during the insertion process.²

MATERIALS AND METHODS

Electrodes

The two electrode arrays included in this study are illustrated in Figure 1. Both arrays carry 16 active contacts and are approximately 22 mm in total length. The contacts are spaced 0.9 mm apart on the Thin Lateral array and 0.85 mm apart on the Helix II device. On both electrodes, the exposed area of each contact is a rectangular plate approximately 0.3 by 0.4 mm in size, which faces the modiolus (the contacts are not circumferential bands). The Thin Lateral electrode is tapered, with cross sectional dimensions of 0.25 × 0.5 mm near the tip, at contact 1, and 0.5 × 0.5 mm at contact 16. This electrode has a slightly curved shape and is designed to track near the lateral wall of the scala tympani during insertion. The curved shape allows the electrode to easily follow the contour of the lateral wall with the tip oriented so that it is less likely to strike the spiral ligament at an angle that might produce injury or impede insertion. The

From the Department of Otolaryngology (C.G.W., P.S.R.), Head and Neck Surgery, Southwestern Medical Center, and Advanced Bionics Corporation (J.K.), Valencia, California, U.S.A.

Support for this study was provided by Advanced Bionics Corporation, Valencia, California, U.S.A.

Editor's Note: This manuscript was accepted for publication July 21, 2005.

Send Correspondence to Dr. Charles G. Wright, Department of Otolaryngology, Head and Neck Surgery, Southwestern Medical Center, 5323 Harry Hines Boulevard, Dallas, TX 75390. E-mail: cgwright@utdallas.edu

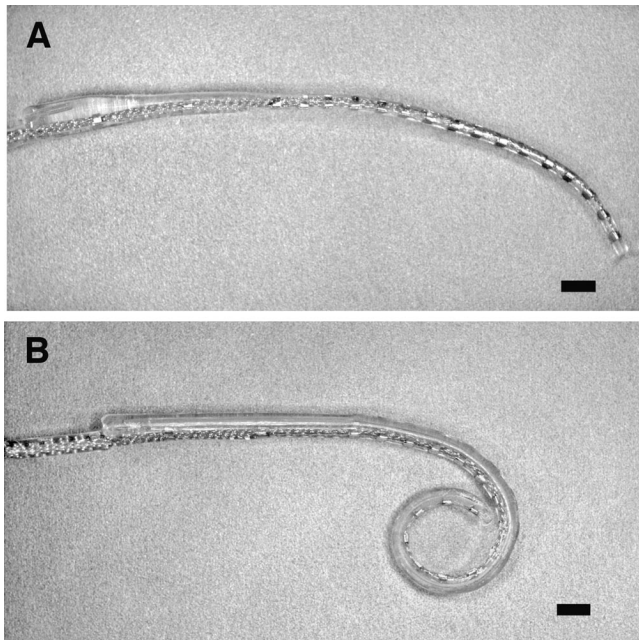


Fig. 1. Photographs of Thin Lateral (A) and Helix II (B) electrode arrays. The Thin Lateral array is slightly curved and designed to track near the lateral wall of scala tympani during insertion. The Helix II electrode is a precurved, coiled electrode that is held straight by a stylet before insertion. Both arrays carry 16 active contacts and are approximately 22 mm in total length. Scale = 1 mm.

curvature of the electrode also helps to prevent rotation during insertion so that the orientation of contacts facing the modiolus is maintained. The Helix II array is smoothly tapered and has cross sectional dimensions of 0.4×0.45 mm at contact 1 and 0.6×0.7 mm at contact 16. The Helix II array is a precurved, coiled electrode that is held straight by a platinum stylet before insertion. The insertion tool for this electrode is designed so that the stylet is withdrawn during insertion, allowing the electrode to regain its precurved shape as it moves through the scala tympani. The contact wiring for both the Helix II and Thin Lateral electrodes is arranged within the silicon carrier so that the electrodes are considerably less flexible in the vertical plane than in the horizontal (lateral) plane, making it less likely that they will deviate "upward" during insertion and injure the basilar membrane or osseous spiral lamina.

Specimen Processing, Electrode Insertion, and Evaluation

The fresh, unfrozen temporal bones used in the study were acquired within 13 hours postmortem. Immediately on arrival in the laboratory, they were trimmed of excess tissue, and the middle ear cavities were opened to provide access to the area of the cochlear promontory. In all specimens, the stapes was removed from the oval window, and the inner ear was perfused with 2.5% glutaraldehyde for fixation of the membranous labyrinth. The bones were then immersed in glutaraldehyde solution at refrigerator temperature for approximately 48 hours before being prepared for electrode insertion. We elected to use fixation in this study to reduce the effects of postmortem autolysis, which may compromise the structural integrity of inner ear tissues and thereby exaggerate insertional trauma. The period of fixation was, however, kept relatively short to minimize any effects of chemical fixation on the physical properties of the cochlear tissues. Glutaraldehyde fixation also has the advantage of providing

good preservation of tissue morphology, which permits more reliable and detailed evaluation of the inner ear structure.

After fixation, the specimens were rinsed in saline and further trimmed to provide access to the round window region of the cochlea. For this study, a wide opening into the middle ear was used to fully visualize the promontory area so as to place the cochleostomy as accurately as possible and thereby avoid cochlear trauma associated with drilling the cochleostomy. This procedure allowed us to be more certain that any trauma observed in the lower basal turn was specifically caused by electrode effects rather than to placement of the cochleostomy.

Cochleostomies were placed 0.5 to 1 mm anterior to the round window margin using a 0.8 mm surgical burr. A cochleostomy size of approximately 1.2 mm was used for both electrodes. Using available anatomic landmarks, we made the effort to place and angulate the cochleostomy openings so as to guide the electrodes into the long axis of the lumen of scala tympani.

Four Thin Lateral and four Helix II electrodes were inserted in this portion of the study. Immediately before insertion, a drop of surgical lubricant (Surgilube, E. Fougera & Co., Melville, NY) was placed at the cochleostomy entrance, and each electrode was also coated with lubricant. The electrodes were then inserted using specially made tools provided by the manufacturer.

Before further manipulation of the specimens, the electrode leads were secured to the bone posterior to the inner ear using cyanoacrylate adhesive to prevent movement of the electrodes during the dissection process. After electrode insertion, the membranous labyrinth was stained by perfusion of the cochlea with 1% osmium tetroxide. The osmium was allowed to remain for 1 to 2 minutes before being rinsed out with 0.9% saline solution. After staining, the otic capsule bone was drilled down to a thin shell around the membranous labyrinth, and the bone covering scala vestibuli of the basal half of the cochlea was drilled away to create a window for viewing the osseous spiral lamina and basilar membrane. The scala vestibuli was opened using a 0.8 mm diamond burr under 8 to 10 power magnification, and care was taken during this process to avoid injury of the cochlear duct, osseous lamina or lateral wall tissues. The bone surrounding the scala tympani and the spiral ligament adjacent to the cochlear duct was kept intact to provide firm support for the lateral wall of scala tympani where the electrode was located. After opening the basal turn, a preliminary assessment of electrode position and the condition of the cochlear structures was made. After the drilling procedure, the specimens were placed in 0.35 M EDTA (ethylenediaminetetraacetic acid) overnight to decalcify the bone still covering the scala vestibuli in the middle and apical portion of the cochlea. This was done because continued drilling to remove bone in the upper part of the cochlea may produce unwanted fractures or other artifacts. The brief decalcification also serves to make the osseous spiral lamina more transparent, thereby increasing visibility of electrodes that may be located beneath it. The decalcified bone overlying the remainder of the scala vestibuli was removed using iris scissors and fine forceps so that the entire length of the basilar membrane and osseous lamina was visible. At that point, the specimen was carefully examined for evidence of electrode trauma, including possible elevation or mechanical injury of the spiral ligament or basilar membrane, basilar membrane perforation, or fracture of the osseous spiral lamina. All specimens were photographed to document the observations. (The silicon carriers of the prototype arrays provided by the manufacturer for our insertion trials were colored blue to increase their visual contrast in photographs of the cochlear dissections.)

To provide quantitative information regarding electrode position, the distance of each of the 16 electrode contacts from the modiolus was measured using a microscale divided into 0.1 mm increments. This was performed with the aid of a stereomicro-

scope by measuring the distance from the medial side of each contact to the point where the osseous spiral lamina joins the modiolar wall. Photographs of each specimen taken from directly above the opened cochlea and looking straight down onto the electrode path were used to estimate the linear insertion depth of each electrode. These measurements were performed using appropriately calibrated NIH Image software (version 1.63) by tracing the inner (modiolar) curvature of the electrode from the inside margin of the cochleostomy to the most apical electrode contact (contact 1). The position of electrode contact 1 was also noted in terms of angular depth on the cochlear spiral. The angular measurements were made by reference to a 0 degree point placed at the basal tip of the cochlear duct and a line drawn from that point through the center of the modiolar apex, as illustrated in Figure 2.

In addition to the preparations described above, three additional temporal bones were prepared for insertion, and the scala vestibuli was opened to permit direct observation of the dynamic behavior of the two electrode prototypes during insertion. Multiple insertion trials were performed with each of these specimens. These insertions were performed by an experienced cochlear implant surgeon (P.S.R.), and they were videotaped for documentation of the observations, which were subsequently confirmed by an independent observer.

RESULTS

Tables I and II present quantitative data regarding the insertion depths and positioning of the four Thin Lateral electrodes inserted into intact temporal bones in this study. These electrodes were found to insert smoothly and easily, and they tended to position themselves appropriately against the lateral wall of the scala tympani with their contacts oriented toward the modiolus, as illustrated in Figure 2. Although the more apical parts of the electrodes closely approximated the lateral wall in all cases, there was some variability in the positioning of the basal contacts, as indicated in Table II. In specimen number one, for example, contacts 10 to 15 were positioned less

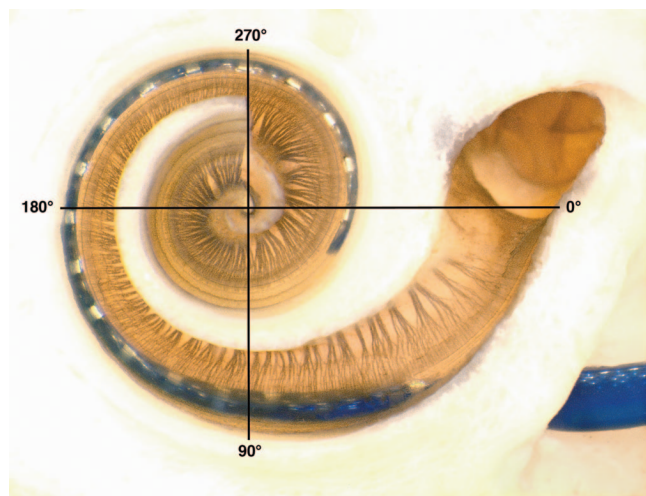


Fig. 2. Cochlear dissection showing a Thin Lateral electrode (preparation 2) in place against lateral wall of scala tympani with no evidence of trauma. Electrode carrier was colored blue to increase visibility of the array beneath the intact basilar membrane. Superimposed coordinates indicate how the angular measurements were made (0 to 180 degree line extends from the basal tip of the cochlear duct through the center of the modiolar apex).

TABLE I.
Thin Lateral, Insertion Depth.

Prep	Angular	Linear
1	335	16.8
2	364	17.4
3	413	18.4
4	360	17.6

Electrode insertion depths for each of the four temporal bone preparations (Prep) in which Thin Lateral electrodes were placed. Measurements of angular insertion depth are given in degrees on the cochlear spiral; linear insertion depths are in millimeters.

than 1 mm from the modiolus because the array was located in a more medial position in the lower basal turn. In other preparations, such as specimen number two, the electrode was in close proximity to the lateral wall of the scala tympani over its entire course.

The insertion depths for the Thin Lateral electrodes (Table I) were such that the electrode contacts were distributed around approximately one full turn (360 degrees) in the base of the cochlea, with the apical-most contact reaching 413 degrees in one case (specimen 4). Even though the Thin Lateral electrode insertions were relatively deep for this electrode design, there was no evidence of trauma to cochlear structures in any of the four specimens. There were no injuries or elevation of the basilar membrane and no indication of displacement or penetration of the spiral ligament by the electrode tip in any case. Figure 3 shows a higher power view of specimen number two in which the electrode is well positioned with no disturbance of soft tissue structures.

TABLE II.
Thin Lateral, Contact Distances From Modiolus.

Contact Number	Preparations			
	1	2	3	4
#1	1.3	1.4	1.1	1.4
#2	1.3	1.4	1.2	1.4
#3	1.4	1.4	1.2	1.4
#4	1.5	1.5	1.2	1.5
#5	1.5	1.5	1.2	1.6
#6	1.3	1.5	1.2	1.6
#7	1.3	1.6	1.2	1.6
#8	1.2	1.6	1.3	1.6
#9	1.0	1.6	1.3	1.5
#10	0.7	1.5	1.3	1.5
#11	0.5	1.4	1.3	1.4
#12	0.3	1.3	1.3	1.3
#13	0.3	1.2	1.1	1.2
#14	0.4	1.1	1.0	1.1
#15	0.7	1.1	0.8	1.0
#16	1.1	1.1	0.8	0.8

Electrode contact distances from the modiolus for each of the four temporal bone preparations in which Thin Lateral electrodes were placed. Contact distances are given in millimeters (mm) as described in the text.



Fig. 3. Higher-power view of the electrode shown in Figure 1. Twelve contacts are visible. Electrode is appropriately positioned against the lateral cochlear wall immediately beneath the basilar membrane. Electrode tip has not impacted the spiral ligament or elevated the basilar membrane.

The electrode shown in Figure 4 illustrates positioning within the scala tympani that was typical of the Helix II arrays evaluated in this study. Information on insertion depth and modiolar proximity for these electrodes is given in Tables III and IV. The Helix II electrodes all tended to show close proximity to the modiolus in the lower basal turn, then deviated outward to contact the lateral wall of the scala tympani in the region between approximately 135 and 225 degrees, and finally approached the modiolus again in the area occupied by the apical contacts of the electrode. As would be expected for an electrode that tracts closer to the modiolus over a substantial part of its length (and therefore has a somewhat tighter spiral), the



Fig. 4. A Helix II electrode seen through the intact basilar membrane and osseous lamina in a cochlear dissection (preparation 4). No evidence of trauma is seen anywhere along the electrode's path. This electrode illustrates the usual positioning observed for this array in this study. That is, the electrode is close to modiolus in the lower base, then deviates outward to contact the lateral wall in the mid-base and finally approaches the modiolus again in the area occupied by the apical portion of the electrode.

TABLE III.
Helix II, Insertion Depth.

Prep	Angular	Linear
1	435	16.1
2	458	17.4
3	450	17.1
4	400	15.9

Electrode insertion depths for each of the four temporal bone preparations (Prep) in which Helix II electrodes were placed. Measurements of angular insertion depth are given in degrees on the cochlear spiral; linear insertion depths are in millimeters.

Helix II arrays tended to reach a greater angular insertion depth (mean depth 436 degrees) than the lateral tracking electrodes (mean depth 368 degrees). The linear insertion depths for the Thin Lateral electrodes were slightly greater than for the Thin Helix arrays because they track the outer cochlear wall, which has the greatest total circumference. As was true for the lateral electrodes, the Helix II arrays produced no discernible trauma in our insertion trials. Even though the electrodes approached the lateral wall in the middle to upper part of the basal cochlear turn, there was no indication of distortion or elevation of the spiral ligament or basilar membrane in those areas and also no evidence of damage near the electrode tip.

The safety and ease of insertion of the Thin Lateral and Helix II electrodes was confirmed in additional insertion trials using temporal bone specimens in which the scala tympani had been opened to permit direct observation of electrode behavior during the insertion process. For

TABLE IV.
Helix II, Contact Distances From Modiolus.

Contact Number	Distance from Modiolus (mm) Preparations			
	1	2	3	4
#1	0.5	0.7	0.3	0.3
#2	0.4	0.4	0.2	0.2
#3	0.5	0.4	0.2	0.1
#4	0.6	0.4	0.2	0.2
#5	0.7	0.4	0.5	0.8
#6	0.8	0.6	1.0	1.2
#7	1.0	1.0	1.4	1.4
#8	1.1	1.4	1.5	1.4
#9	1.0	1.4	1.4	1.3
#10	1.0	1.3	1.3	1.0
#11	0.8	1.3	0.9	0.7
#12	0.6	1.1	0.7	0.4
#13	0.3	0.8	0.2	0.1
#14	0.1	0.5	0.05	0.05
#15	0.2	0.2	0.05	0.2
#16	0.4	0.2	0.1	0.4

Electrode contact distances from the modiolus for each of the four temporal bone preparations in which Helix II electrodes were placed. Contact distances are given in millimeters (mm) as described in the text.

these insertions, the specimens were positioned so as to allow visualization of the advancing electrode under approximately 10 power magnification using a dissection microscope. During multiple trials, there was no indication of any disturbance of soft tissues inside the cochlea or impingement of the electrode tip against lateral wall or modiolar structures.

DISCUSSION

The prototype electrodes evaluated in this study performed favorably in the temporal bone insertion trials described above. No evidence of insertional trauma was seen in specimens implanted with either the Thin Lateral or Helix II arrays. Major types of intracochlear trauma, such as perforation of the basilar membrane with excursion of the electrode into the scala vestibuli or fracture of the osseous spiral lamina, were not observed. In addition, neither electrode was found to elevate the basilar membrane or spiral ligament or to produce tears of the basilar membrane at its attachment to the lateral wall. Thus, according to the trauma rating scale developed by Eshraghi et al.,³ all specimens included in the study would receive a rating of zero, for no observable trauma.

The relatively small diameter of the Thin Lateral and Helix II electrodes is likely to be an important factor contributing to their favorable performance with regard to trauma. As has been observed in previous studies, thicker arrays are more likely to elevate or tear the basilar membrane or spiral ligament when they approach the lateral wall of the scala tympani.⁴ A larger diameter also increases electrode surface area, resulting in more friction with cochlear tissues, making it more likely that an electrode will encounter sufficient resistance during insertion to produce buckling that may damage the basilar membrane or fracture the osseous spiral lamina.^{5,6}

In addition to their smaller diameter, these arrays have other features designed to reduce the occurrence of trauma. As noted above, the slightly curved shape and lateral flexibility of the Thin Lateral electrode allows it to follow the curvature of the lateral wall in such a way that its tip is less likely to strike the lateral wall at an angle that may produce injury or impede the progress of the array through the scala tympani. Because the stylet of the Helix II electrode is withdrawn from the array during the insertion process, the electrode tip curls medially, away from the lateral wall, as it moves through the scala tympani, thereby decreasing the likelihood of spiral ligament

trauma. The Helix II electrode is also designed not to directly contact the modiulus during insertion, making it less likely to fracture the modiolar wall.

Given the absence of trauma in the temporal bone trials described above, these electrodes appear promising for clinical use. The Thin Lateral electrode is designed to be atraumatically inserted to a depth of approximately 360 degrees without risk of modiolar injury. It therefore provides electrical stimulation limited to the basal turn, making it suitable for patients with residual low-frequency hearing who may benefit from combined electrical and acoustic stimulation. Because this electrode tracks the lateral wall, it may also be appropriate for insertion by way of the round window, thereby avoiding much of the trauma associated with placement of a cochleostomy. The Helix II electrode, on the other hand, would be appropriate for use in patients in whom a somewhat deeper insertion depth is desirable to more efficiently stimulate low-frequency neurosensory structures. Because this electrode is designed to minimize direct contact with either the lateral wall of scala tympani or the modiulus, increased insertion depth can be achieved with little or no risk of increased trauma.

CONCLUSION

The Thin Lateral and Helix II electrode arrays performed favorably in insertion trials performed during this study. They therefore appear promising for clinical use, particularly in patients with residual hearing in whom atraumatic electrode insertion is an important objective.

BIBLIOGRAPHY

1. Gantz BJ, Turner CW. Combining acoustic and electrical hearing. *Laryngoscope* 2003;113:1726–1730.
2. Wright CG, Roland PS. Temporal bone microdissection for anatomic study of cochlear implant electrodes. *Cochlear Implants Int.* 6:159–170.
3. Eshraghi AA, Yang NW, Balkany TJ. Comparative study of cochlear damage with three perimodiolar electrode designs. *Laryngoscope* 2003;113:415–419.
4. Zappia JJ, Niparko JK, Oviatt DL, et al. Evaluation of temporal bones of a multichannel cochlear implant patient. *Ann Otol Rhinol Laryngol* 1991;100:914–921.
5. Shepherd RK, Clark GM, Pyman BC, Webb RL. Banded intracochlear electrode array: evaluation of insertion trauma in human temporal bones. *Ann Otol Rhinol Laryngol* 1985; 94:55–59.
6. Kennedy DW. Multichannel intracochlear electrodes: mechanism of insertional trauma. *Laryngoscope* 1987;9: 42–49.