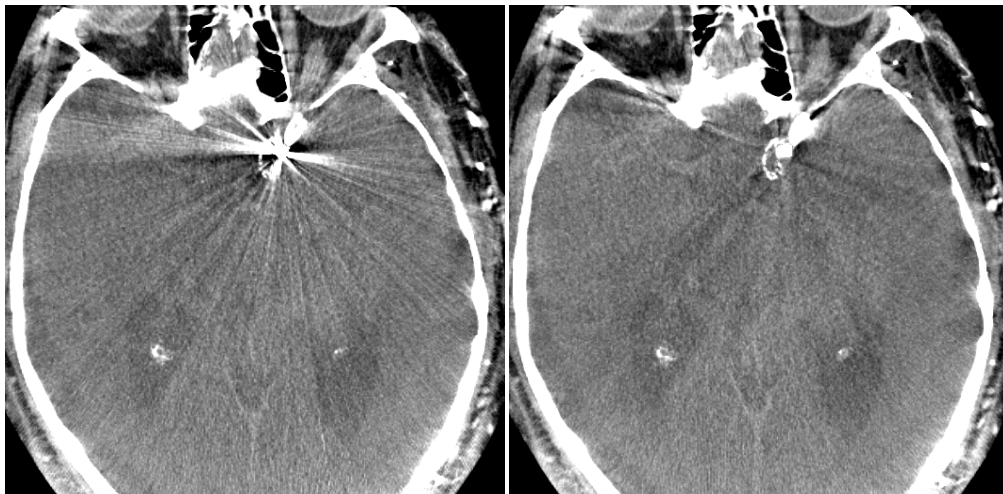


# METAL ARTIFACT REMOVAL IN C-ARM CONE-BEAM CT

GROUP 4  
CAROLINA CAY-MARTINEZ, MARTA WELLS

## REPORT # 1 CLINICAL BACKGROUND



CT image of coil before and after MAR algorithm application  
Image provided by Radvany, MD

THE JOHNS HOPKINS UNIVERSITY  
ADVANCED COMPUTER INTEGRATED SURGERY

PROJECT ADVISORS:  
JEFFREY H. SIEWERDSEN, PH.D.  
MARTIN RADVANY, MD (INTERVENTIONAL RADIOLOGY)  
TINA EHTIATI, PH.D. (SIEMENS HEALTHCARE)

The use of CT imaging in the surgical environment provides fast, low-dose imaging for safer more accurate surgical treatment. Neurovascular interventions, minimally invasive interventional radiology procedures performed inside the blood vessels of the head and neck, include treatment for aneurysms, intracranial stenosis, and arteriovenous malformations (AVMs), among others. Treatments of these diseases involve the use of clips, coils, stents and other metal-based materials, which can cause metal artifacts and degradation of image quality. Following is a clinical background on interventional radiology procedures affected by metal artifact in CT images.

**I. Aneurysms**

**Pathophysiology, Morphology, and Location**

Aneurysms in the brain occur when there is a weakened area in the wall of a blood vessel. An aneurysm may be present from birth (congenital) or it may develop later in life, such as after a blood vessel is injured. A cerebral aneurysm most commonly occurs in an artery located in the front part of the brain that supplies oxygen-rich blood to the brain tissue. Normal artery walls are made up of three layers; in an aneurysm the wall is thin and weak due to an abnormal loss or absence of the muscular layer of the artery wall, leaving only two layers.

There are many different types of aneurysms, and the most common type is called a berry aneurysm. This type can vary in size from a few millimeters to over a centimeter; giant berry aneurysms can even be larger than 2 centimeters. Fusiform aneurysms are diffuse bulges of the vessel wall involving most of the entire circumference of the blood vessel itself. They may rupture or cause stroke-like symptoms when they compress the surrounding brain. Such aneurysms can occur in any blood vessel that supplies the brain. Mycotic aneurysms are rare and result from an infection. The infection damages and weakens the blood vessel, thereby increasing the associated risk of rupture. This infection occurs most commonly as a complication of subacute bacterial endocarditis (a heart infection). Traumatic aneurysms occur when a cerebral blood vessel incurs trauma from a head injury. The damaged blood vessel weakens at the site of injury which may cause it to rupture.

**Incidence and Alternative Treatments**

Every year, an estimated 30,000 people in the United States experience a ruptured cerebral aneurysm, and up to 6 percent of the population may be living with an unruptured aneurysm. In adults, females are more likely to have aneurysms, and they are most prevalent in people ages 35 – 60, but can occur in children as well. Aneurysms are most prevalent in people ages 50 to 60. About 40 to 50 percent of patients with ruptured aneurysms survive; 20 percent of these patients will have no permanent physical deficits.

**Neurovascular Intervention: Surgical Clipping**

The goal of clipping is to place a small metallic clip or clips, usually made of titanium, along the neck of the aneurysm. This prevents blood from entering into the aneurysm sac so that it can no longer pose a risk for bleeding. Over the past 50 years, repeatedly refined designs of increasingly pure titanium clips have been manufactured providing the neurovascular surgeon with numerous clip shape and size choices that can either singly or in combination address most, but not all, aneurysms. The clip has a spring mechanism which allows the two "jaws" of the clip to close around either side of the aneurysm, thus separating the aneurysm from the parent blood vessel. Once an aneurysm is clipped, the clip remains in place for life. The aneurysm will

Patent Application Publication Nov. 24, 2011 Sheet 5 of 6 US 2011/0288571 A1

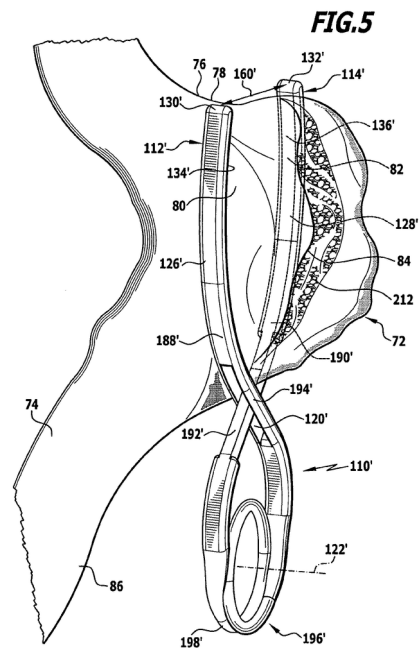


Image provided by Patent Application: Surgical clip and surgical method for treating an aneurysm  
C. Gay, M.D. WENS

shrink and scar down permanently after clipping.

The patient is put under general anesthesia, and then prepped for surgery. The head is stabilized to make sure it does not move during the surgical procedure. Depending on the location of the aneurysm, an incision is typically made behind the hairline or on the back of the head. A small portion of the hair is usually shaved along the line of the incision. Next, a section of the cranium is removed using a specialized saw, giving access to the dura, the lining over the brain. The dura is then opened to expose the brain surface. The surgeon approaches the aneurysm in the cleft between the skull and the brain and not through brain tissue. The aneurysm is then carefully separated from the normal blood vessels and brain. Once it has been fully exposed, the aneurysm is clipped closed, which keeps blood from entering the aneurysm. As a result, future bleeding is prevented and nearby brain tissue is protected from further damage. The cranial section is then returned securely in place using thin metal plates and screws, and the wound is closed.

### Neurovascular Intervention: Endovascular Coiling

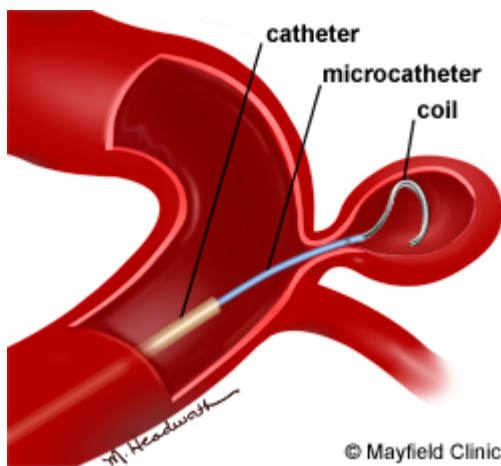


Image provided by the Mayfield Clinic:  
<http://www.mayfieldclinic.com/PE-Coiling.htm>

Endovascular coiling blocks blood flow to an aneurysm to prevent bursting. Coiling does not require open surgery. A catheter is inserted into an artery in the groin, then advanced into the affected artery in the brain, using X-rays and contrast agent fluoroscopy for guidance. The coils used in this procedure are typically made of flexible platinum and are shaped like thin springs ranging in size from about twice the width of a human hair (largest) to less than one hair's width (smallest). The coil is attached to a microcatheter that is inserted through the initial catheter. When the microcatheter has reached the aneurysm and has been inserted into the aneurysm, an electrical current is passed through the coil to separate the coil from the catheter. The coil conforms to the aneurysm shape and seals off the opening of the aneurysm. It may take several coils to seal off the aneurysm. The coil is left in place permanently in the aneurysm. Depending on the size of the aneurysm, more than one coil may be needed to completely seal off the aneurysm.

## II. Intracranial Stenosis

### Pathophysiology, Morphology and Location

Intracranial stenosis is a narrowing of an artery inside the brain that can lead to ischemic stroke. Stenosis is caused by a buildup of plaque (atherosclerosis) inside the artery wall that reduces blood flow to the brain. Atherosclerosis that is severe enough to cause symptoms carries a high risk of stroke and can lead to brain damage and death.

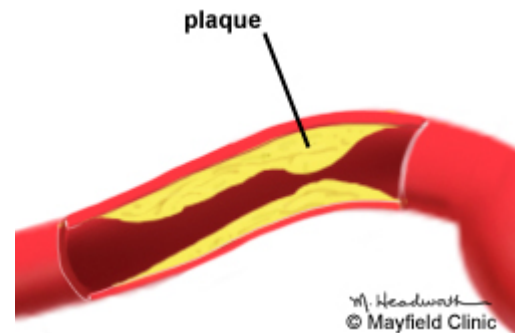
### Incidence and Alternative Treatment

Intracranial stenosis is responsible for 8 to 10% of strokes in the United States and exhibits increased prevalence among African Americans, Asian Americans, and Hispanics. Patients with intracranial artery disease tend to be younger than those with carotid artery disease in the neck.

Treatment options for intracranial stenosis vary according to the severity of the narrowing and presence or absence of stroke-like symptoms. At-risk patients are first treated with medication and educated regarding lifestyle changes that could reduce their risk of stroke. Surgery is limited to patients whose symptoms do not respond to medication. Surgical treatment can include bypass grafting to increase blood flow to the brain distal to the stenosis. Typically, a superficial temporal artery-to-middle cerebral artery (STA-MCA) bypass is used. Less commonly, when the demand for blood flow is high, a high-flow bypass is placed using a large caliber vein or artery for the graft.

### Neurovascular Intervention: Intracranial Angioplasty

Balloon angioplasty is a minimally invasive endovascular procedure that compresses the plaque and widens the inner diameter of the artery. A catheter is inserted into the femoral artery in the groin under angiography. The catheter is then advanced through the bloodstream to where the plaque-narrowed artery is located. A small balloon is then slowly inflated within the narrowed artery to dilate it and compress the plaque against the artery wall. The aim is to reduce stenosis by up to 50%, as a small increase of the vessel diameter results in large increases in blood flow to the brain. The balloon is then deflated and removed. There are numerous technical drawbacks to angioplasty, including immediate elastic recoil of the artery, dissection, acute vessel closure, residual stenosis after the procedure, and high restenosis rates.



### Neurovascular Intervention: Intracranial Stenting

In some cases, after the balloon angioplasty is removed, a self-expanding mesh-like tube called a stent is placed over the plaque, holding open the artery.

Bare metal balloon-mounted (coronary) stents and drug-eluting stents have also been used to treat symptomatic intracranial stenosis. However, reports of their use have been limited to case reports and small series. Bare metal balloon-mounted stents are limited by their rigidity, making delivery to intracranial lesions technically difficult. Drug-eluting stents are limited by the lack of long-term safety data and risk of in-stent thrombosis. The Wingspan stent system includes a self-expanding, metal (nitinol) mesh in the shape of a tube. Nitinol is a metal alloy of nickel and titanium that has the unique properties of shapes memory and superelasticity. It is currently the only FDA-approved device for treating symptomatic intracranial stenosis. Wingspan is also the most well studied of the available devices, and the existing data have indicated high rates of technical success, but long-term efficacy for stroke prevention has not yet been adequately assessed and further studies are needed.

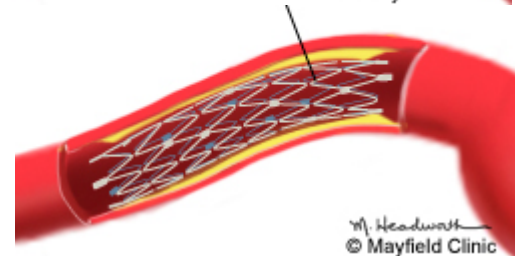
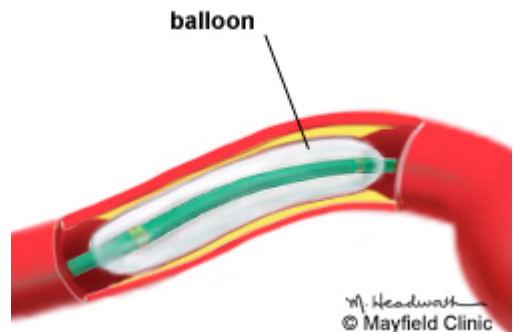


Image provided by the Mayfield Clinic:  
<http://www.mayfieldclinic.com/PE-IntracranialStenosis.htm>

Patients with 70% to 99% stenosis are at highest risk on medical therapy; the stenting complication rates are similar between patients with moderate and severe stenosis and as such, the benefit of stenting is likely to be greater in the severe stenosis group.

## III. Arteriovenous Malformations (AVMs)

### Pathophysiology, morphology, and location

Arteriovenous malformations are defects of the circulatory system that are generally believed to arise during embryonic or fetal development or soon after birth. They are comprised of snarled tangles of arteries and veins that lack an intervening capillary network. The absence of capillaries creates a short-cut for blood to pass directly from arteries to veins: arteries dump blood directly into veins through a passageway called a fistula. The flow rate is uncontrolled and extremely rapid, too rapid to allow oxygen to be dispersed to surrounding tissues. When starved of normal amounts of oxygen, the cells that make up these tissues begin to deteriorate, sometimes dying off completely. Although AVMs can develop in many different sites, those located in the brain or spinal cord can have especially widespread effects on the body. AVMs damage the brain or spinal cord through three basic mechanisms: by reducing the amount of oxygen reaching

neurological tissues, by causing bleeding (hemorrhage) into surrounding tissues, and by compressing or displacing parts of the brain or spinal cord.

**Incidence and Alternative Treatment**

AVMs of the brain or spinal cord (neurological AVMs) are believed to affect approximately 300,000 Americans. They occur in males and females of all racial or ethnic backgrounds at roughly equal rates. Three surgical options exist for the treatment of AVMs: conventional surgery, radiosurgery, and endovascular embolization. The choice of treatment depends largely on the size and location of an AVM. Conventional surgery involves entering the brain or spinal cord and removing the central portion of the AVM, including the fistula, while causing as little damage as possible to surrounding neurological structures. This surgery is most appropriate when an AVM is located in a superficial portion of the brain or spinal cord and is relatively small in size. AVMs located deep inside the brain generally cannot be approached through conventional surgical techniques because there is too great a possibility that functionally important brain tissue will be damaged or destroyed. Radiosurgery is a less invasive therapeutic approach. It involves aiming a beam of highly focused radiation directly on the AVM. The high dose of radiation damages the walls of the blood vessels making up the lesion. Over a period of several months, the irradiated vessels degenerate and eventually close, resolving the AVM.

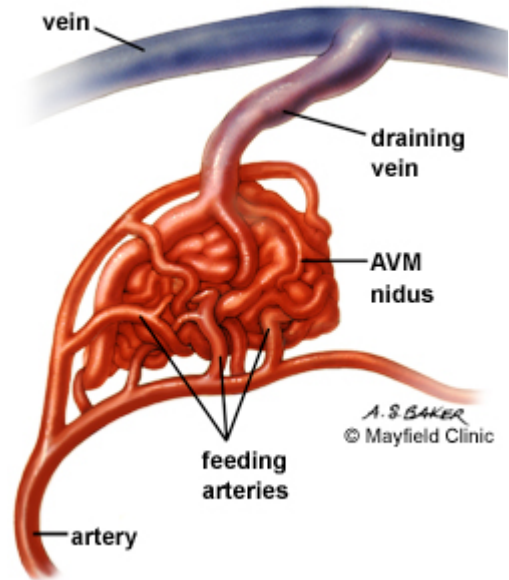


Image provided by the Mayfield Clinic:  
<http://www.mayfieldclinic.com/PE-AVM.htm>

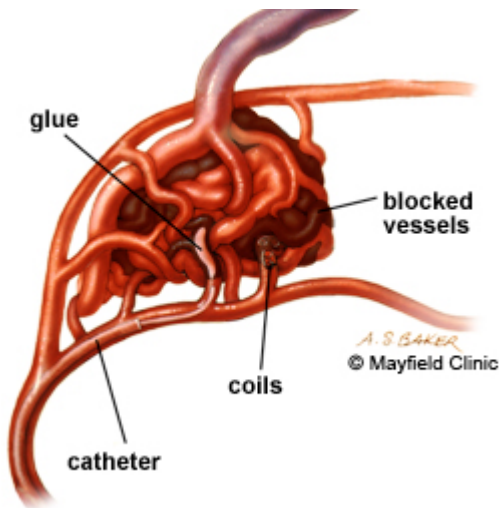


Image provided by the Mayfield Clinic:  
<http://www.mayfieldclinic.com/PE-AVM.htm>

**Neurovascular Intervention: Embolization**

Endovascular embolization is also less invasive than conventional surgery and offers safer treatment options for some AVMs located deep inside the brain. In endovascular embolization the interventionalist guides a catheter through the arterial network until the tip reaches the site of the AVM. An embolus is introduced that travels through the blood vessels, eventually becoming lodged in the fistula, correcting the abnormal pattern of blood flow. The embolic materials used to create an artificial blood clot in the center of an AVM include fast-drying biologically inert glues, fibered titanium coils, and tiny balloons. Since embolization usually does not permanently ablate the AVM, it is usually used as an adjunct to surgery or to radiosurgery to reduce the blood flow through the AVM and make the surgery safer.

Embolization frequently proves incomplete or temporary, although in recent years new embolization materials have led to improved results. Radiosurgery often has incomplete results as well, particularly when an AVM is large, and it poses the additional risk of radiation damage to

surrounding normal tissues. Moreover, even when successful, complete closure of an AVM takes place over the course of many months following radiosurgery. During that period, the risk of hemorrhage is still present. However, both techniques offer the possibility of treating deeply situated AVMs that had previously been inaccessible. In many individuals, staged embolization followed by conventional surgical removal or by radiosurgery is an option, resulting in further reductions in mortality and complication rates.

#### IV. Other Sources of Metal Artifact: Dental Fillings

The presence of metallic dental fillings is prevalent in head and neck CT and generates bright and dark streak artifacts in reconstructed CT images. Important information is lost both near dental fillings as well as in the periphery of the image. The two main causes of such severe metal streak artifacts are: (i) “photon starvation” (near complete absorption of X-rays by the filling, resulting in a signal at or below the electronic noise level of the detector); and (ii) “beam hardening” (a strong shift in the energy spectrum of the transmitted X-ray beam resulting in a detector response that is inconsistent with other projection data).

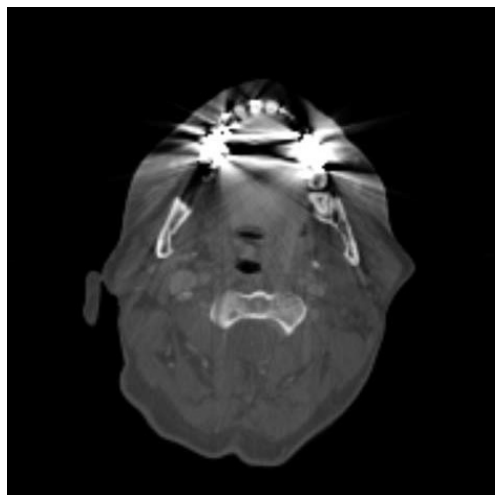


Image provided by Abdoli *et al.*: Metal artifact reduction in CT-based PET attenuation correction

#### V. Other Sources of Metal Artifact: iCT Stabilizing Pins

New CT technology, software, hardware, and high-resolution scanning including intraoperative angiography and CT perfusion mapping are now available with low radiation exposure and short scan times compared with previous techniques. These technical developments enable the surgeon to work within a closed intraoperative network based on an iCT navigation system. Combination of iCT scanning with navigation systems allows for an intraoperative update of the registration during surgery and is a new and promising tool of iCT technology. Intraoperative CT scanning requires a special fixation system of the head to avoid artifacts that may lead to reduced image quality. For most of the iCT scanners, a carbon-fiber Mayfield clamp and titanium pins are used, which produce less severe artifacts than steel. To avoid pin-related artifacts, the position of the headholder clamp may be modified, but alternative positioning of the holder must weigh the compromise against suboptimal head fixation and stability. Some artifact-free pin holders have been developed to avoid pin-related artifacts without compromise in regard to head fixation; however titanium pins are still utilized in some procedures.

#### VI. Summary

In summary, a number of prevalent pathologies presenting a major disease burden in North America (including arterial aneurysms, stenosis, and AVMs) may be treated with a variety of interventional techniques (including clips, coiling, stenting, and other measures). Such interventions are often performed with spatial localization and guidance provided by X-ray CT imaging methods available in the interventional suite. However, the interventions often utilize devices consisting of dense material (metal) that can result in artifacts that degrade CT image quality due to effects such as “photon starvation” and “beam hardening.” Such artifacts can challenge the visibility of structures of interest and reduce the precision and effectiveness of the intervention. As such, the development of metal artifact correction techniques are an important aspect of a high-performance interventional image guidance system.

## References

1. <http://www.harperhutzet.org/?id=379&sid=1>
2. [http://www.ninds.nih.gov/disorders/avms/detail\\_avms.htm](http://www.ninds.nih.gov/disorders/avms/detail_avms.htm)
3. <http://circ.ahajournals.org/content/94/5/1167.long>
4. <http://www.intelihealth.com/IH/ihtIH/WSIHW000/9339/10861.html>
5. <http://www.fda.gov/MedicalDevices/ProductsandMedicalProcedures/DeviceApprovalsandClearances/Recently-ApprovedDevices/ucm078508.htm>
6. <http://www.ncbi.nlm.nih.gov/pubmedhealth/PMH0002387/>
7. <http://www.ncbi.nlm.nih.gov/pubmedhealth/PMH0004619/>
8. <http://www.aans.org/Patient%20Information/Conditions%20and%20Treatments/Cerebral%20Aneurysm.aspx>
9. <http://www.bafound.org/node/116>
10. [http://www.hopkinsmedicine.org/healthlibrary/test\\_procedures/neurological/endovascular\\_coiling\\_92,P08768/](http://www.hopkinsmedicine.org/healthlibrary/test_procedures/neurological/endovascular_coiling_92,P08768/)
11. <http://www.mayfieldclinic.com/PE-IntracranialStenosis.htm>
12. <http://www.mayoclinic.com/health/brain-aneurysm/DS00582/DSECTION=treatments-and-drugs>
13. [http://www.stroke.org/site/DocServer/SCU\\_-\\_May-June\\_2006.pdf?docID=5168](http://www.stroke.org/site/DocServer/SCU_-_May-June_2006.pdf?docID=5168)
14. <http://www.faqs.org/patents/app/20110288571>
15. <http://www.mayfieldclinic.com/PE-Coiling.htm>
16. <http://www.ncbi.nlm.nih.gov/pubmed/19301958>
17. [http://www.surgicalneurologyint.com/temp/SurgNeurolInt3365-7787695\\_213756.pdf](http://www.surgicalneurologyint.com/temp/SurgNeurolInt3365-7787695_213756.pdf)