

Literature Review

Robotic Bone Drilling Assessment

Shain Bannowsky

20 April, 2017

Papers:

- Bercin S; Kutluhan A; Bozdemir K; Yalciner G; Sari N; Karamese Ö, “Results of revision mastoidectomy.” *Acta Oto-Laryngologica* 129.2 (2009): 138-41. Web.
- Bell, Brett, Christof Stieger, Nicolas Gerber, Andreas Arnold, Claude Nauer, Volkmar Hamacher, Martin Kompis, Lutz Nolte, Marco Caversaccio, and Stefan Weber. "A Self-developed and Constructed Robot for Minimally Invasive Cochlear Implantation." *Acta Oto-Laryngologica* 132.4 (2012): 355-60. Web.
- Ansó, Juan, Cilgia Dür, Kate Gavaghan, Helene Rohrbach, Nicolas Gerber, Tom Williamson, Enric M. Calvo, Thomas Wyss Balmer, Christina Precht, Damien Ferrario, Matthias S. Dettmer, Kai M. Rösler, Marco D. Caversaccio, Brett Bell, and Stefan Weber. "A Neuromonitoring Approach to Facial Nerve Preservation During Image-guided Robotic Cochlear Implantation." *Otology & Neurotology* 37.1 (2016): 89-98. Web.

Review Paper

Introduction:

Drilling into the mastoid process is a risky procedure because of unintended damage to surrounding tissues, and the development of postoperative complications. The mastoid is located at the lateral sides of the skull and dorsal to the ear, and is in close proximity to sensitive structures. Surgeons operating on the mastoid take care not to drill into the ear canal, facial nerve, or into the brain. Damage to the facial nerve is detrimental to the patient’s quality of life, and threatens their economic and mental wellbeing, since the nerve controls facial muscles necessary for proper speech. Submillimeter accuracy is necessary when operating in this area, due to the small size of the nearby anatomy. For example, the facial nerve is approximately 2mm in diameter.^[1]

Drilling of the mastoid is referred to as a mastoidectomy, and is done to treat mastoiditis or to prepare a cochlear implant. Mastoiditis is the infection of the air cells in the mastoid process. A mastoidectomy is necessary to remove the diseased tissue responsible for mastoiditis, in order to prevent the infection from spreading. A mastoidectomy is also necessary to access the inner ear, in order to install a cochlear implant.

Surgeons may use assistive robots to improve their performance in surgery and improve patient prognosis. Robots may provide hand tremor elimination, such as the Galen robot developed at Johns Hopkins University by Kevin Olds.^[2] The robot reduces the sporadic movements of the surgeon's hand in order to improve the precision of their movements. Robots may also implement virtual fixtures to mitigate the risk of patient injury. Generally, virtual fixtures limit the movement of the robot by either defining areas it may not go, areas it may move slowly in, or both. Virtual fixtures require the registration of the patient's scans in order to function. The Galen robot is capable of both hand tremor elimination and enforcing virtual fixtures.

Robotic assistance helps surgeons avoid harming the patient by reducing the likelihood of them unintentionally drilling into the surrounding anatomy. Virtual fixtures may limit the permitted movement of tools to the infect air cells or to the path needed to insert a cochlear implant, while forbidding movement to near the facial nerve, the ear canal, and through the temporal bone. This is very important for the treatment of mastoiditis, since virtual fixtures can help surgeons completely eliminate diseased tissue by clearly defining the total volume to be removed. Complete removal of the tissue helps prevent recurring infection and the need for revision surgeries, which carry elevated risks of complications.^[3] In addition, neuromonitoring instruments have been developed to detect the facial nerve, based on its proximity. These sorts of tools have been used in other forms of surgery whenever a risk exists for nerve damage.

The goal of the project is to assess the safety, effectiveness, and speed of mastoidectomies performed with the Galen robot, in the context of treating mastoiditis. The safety of the patient is paramount, damaging the facial nerve may cause severe facial paralysis. Safety is assessed qualitatively by determining whether the simulated facial nerve in a surgical phantom has been damaged. Safety is also assessed quantitatively by recording the closest distance the tool approached the facial nerve. Effectiveness is measured by the quantity of diseased tissue removed, and is determined using postoperative scans. Increased effectiveness

would reduce the likelihood of requiring revision surgery. The speed of robotically assisted mastoidectomies are compared against the speed of freehand surgery. Three groups of subjects, sorted by surgical ability, will perform a simulated mastoidectomy on a surgical phantom. Each subject will perform the mastoidectomy with varying degrees of robotic assistance, such as freehand, hand tremor elimination, and tremor elimination with virtual fixtures.

Three papers have been selected for this literature review. Two come from the medical journal *Acta Oto-Laryngologica*, and are about the complications of revision mastoidectomies, and a surgical robot designed for cochlear implants. The final paper is from the *Otology & Neurotology* research journal, and describes the design of an innovative design for a neuromonitoring probe.

Paper 1: “Results of revision mastoidectomy.”

Introduction:

This paper focuses on the outcomes of revision mastoidectomies, in the context of chronic otitis media (COM). The primary objective is to restore hearing in the infected ear. The surgical procedure is very similar to that for treating mastoiditis, and includes the complete removal of air cells near the ear canal. In addition, avoiding damage to neurovascular structures is an important goal in these surgeries. Therefore, surgical interventions for COM and mastoiditis share similar objectives and procedures.

Methods:

Patients are differentiated based on whether their ear canal walls are intact (ICW) or not (CWD). Only those who had revision mastoidectomy were included in the study, while those who had other kinds of ear surgery were excluded. Patients were not differentiated based on the presence of cholesteatomas (noncancerous skin growths^[4]). None had infection in both ears. A total of 35 patients were part of the study.

Results:

Of the total 35 patients with revision mastoidectomies, 19 reported ear discharge, 9 reported ear aches, and 6 reported vertigo. Regarding complications before revision, 24 patients

had cholesteatomas, and 10 had facial nerve dehiscence (the facial nerve is exposed). 29 were successfully treated with no chronic cholesteatoma or disease. According to the article, persistent cholesteatoma and narrow meatoplasties were the two most common reasons for revision surgery.

Table I. Causes of failure of previous surgery.

Cause	CWD (n=21) (%)	ICW (n=14) (%)	Total (n=35) (%)
Persistent sinodural angle air cells	15 (71.4)	8 (57.1)	23 (65.7)
High facial ridge	14 (66.7)	–	
Persistent tegmental air cells	12 (57.1)	6 (42.9)	18 (51.4)
Recurrent or persistent cholesteatoma	17 (80.9)	11 (78.6)	28 (80)
Persistent mastoid apex air cells	11 (52.4)	8 (57.1)	19 (54.3)
Narrow meatoplasty	17 (80.9)	–	
Closed supratubal recess	15 (71.4)	9 (64.3)	24 (68.6)
Open eustachian orifice	11 (52.4)	–	
Inadequate canalplasty	14 (66.7)	8 (57.1)	22 (62.9)
Anulus or tympanic membrane remnant	12 (57.1)	–	

Figure 1: Table describing causes of mastoidectomy failure. Figure from "Results of revision mastoidectomy"

Discussion:

The authors describe how the ear’s ability to clean and dry itself is important for preventing revision surgery, and how surgeons may alter tympanomastoid anatomy to prevent chronic disease. The paper’s assessment of the causes of revision surgery agree with previous assessments. The causes of needing revision surgery can be summarized as the inadequate removal of diseased air cells, insufficient self-cleansing of the ear, and incomplete removal of cholesteatoma. The most likely locations of persistent diseased air cells are described, as well as recommendations for anatomical alterations to promote proper healing and function. These recommendations include widening the meatus inside the ear, lowering the facial ridge, removing excess tissue of the external auditory canal, and obliteration of the eustachian tube.

Review:

This paper provides insight on how mastoidectomies fail, requiring revision surgery. The identification and removal of cholesteatoma is an important factor in preventing the need for a revision. Additionally, the shape of healthy tissue is more important than expected, since proper hygiene of the surgical area is important in preventing chronic disease. Most of the alterations to healthy structures support the proper ventilation of the mastoid, with an exception being the obliteration of the eustachian tube. The obliteration is necessary to keep the mastoid clean and dry, by preventing mucus from entering from the tube.

The evaluation of mastoidectomy failure agrees with the evaluations by previous authors, and the elimination of diseased air cells is important for the patient's health. This complete elimination also helps make revision surgery unnecessary. While outside the scope of the project, future studies may assess the quality of a surgeon's alterations to healthy tissues to promote healing.

Paper 2: "A Self-developed and Constructed Robot for Minimally Invasive Cochlear Implantation"

Introduction:

The paper begins by describing the direct cochlear access (DCA) and how to minimize the invasiveness of mastoidectomies, in the context of installing a cochlear implant. Earlier research by Warren et al suggests that the mastoidectomy needs to be only a tunnel to access the middle ear. Such a tunnel requires surgical accuracy under 0.5mm to avoid unintentional damage. A variety of robotic assistance techniques have been evaluated in other papers, such as the use of fiducials, constrained tool pathing, and autonomous surgery. Ultimately these were deemed insufficient, and unable to drill the tunnel with the required accuracy. The authors developed and evaluated their own microsurgery robot for tunneling through the mastoid.

Methods:

The microsurgery robot is mainly a serial arm with 5 degrees of freedom, and designed to be mounted on OR tables. The robot has force sensors to detect surgeon input, and its controller is outside the operating theater.

The robot was evaluated using 8 human heads, drilling into each temple. Titanium screws were used as reference markers. Each temple was scanned and important anatomical features were identified, such as the chorda tympani, external auditory canal, facial nerve, ossicles, and the round window. The head and the scan were registered using a surface matching algorithm.

Before each procedure, the head was held in a clamp. A registration points was physically aligned with each fiducial. After registration, the head was prepared for surgery. A starter hole was created before drilling the tunnel, to improve the accuracy of the mastoidectomy. The drill was cooled continuously with pure water. After the procedure, a titanium wire was placed in the tunnel, which helps determine the axis of the DCA in postoperative imaging. Pre- and postoperative scans were aligned using the fiducials. To assess damage, the surface models of important structures were compared with the trajectory of the DCA. Manual inspection would confirm or deny any suspected damage.

Results:

15 tunnels were successfully drilled. The error in tunnel entrance is $0.44\text{mm} \pm 0.21\text{mm}$, and in the target it's $0.56\text{mm} \pm 0.41\text{mm}$. 3 cases had suspected facial nerve damage, but this was confirmed visually in only 1 case. The authors were unable to evaluate thermal damage to the nerve. Registration and drilling originally took 50min, but was improved to $25\text{min} \pm 12\text{min}$ with practice.

Table II. Comparison of DCA accuracy results.

Reference	Model	Error at target (mm)	Method
Schipper et al. 2004 [5]	Cadaver	1.6	Hand-guided
Labadie et al. 2005 [6]	Temporal bone	Not reported	Hand-guided
Labadie et al. 2009 [9]	Temporal bone	0.36 ± 0.18	Template
Majdani et al. 2009 [10]	Temporal bone	0.78 ± 0.29	Kuka KR3
Klenzner et al. 2009 [11]	Temporal bone	0.25 (virtual)	Staeubli RX90CR
Baron et al. 2010 [12]	Phantom	0.62 ± 0.25	Kuka KR3, Mitsubishi RV-3S
This work	Cadaver	0.56 ± 0.41	Custom built

DCA, direct cochlear access.

Figure 2: Comparison of accuracy between this and other studies, taken from "A self-developed and constructed robot for minimally invasive cochlea implantation"

Discussion:

The purpose of the study is to assess the accuracy of the custom microsurgery robot built by the authors. The goal was to place cochlear electrodes at the target, but unfortunately the robot did not have the required accuracy of less than 0.5mm. The authors believe the visual alignment of fiducials and calibration errors are the main sources of error, and plan to correct these by implementing a new registration technique without human input, and a visual tracking system for tool position. The addition of more fiducials and a nerve monitor are planned for the next iteration of the robot.

Review:

This article is useful because it evaluates techniques used in robotic surgery, within the context of minimally invasive mastoidectomy. The high accuracy of the system is very beneficial to the patient, since unintentional damage is always a concern for mastoidectomies. Nonetheless, facial nerve damage can still happen even with the sub-millimeter accuracy of the microsurgery robot. It wouldn't be fair to judge the system on its ability to avoid critical structures since it wasn't included in its original design intent. The clinical version of the robot is designed with virtual fixtures to limit the tool's path, and with redundant navigation systems to improve navigation. More importantly, the authors provide insight as to why their robot failed to meet the accuracy requirements.

Their findings suggest robotic surgery achieves its maximum potential for precision when human intervention is minimized, as was the case in their registration process. In addition, mechanisms with feedback may allow for superior surgical performance, compared to relying on the robot's controller alone. As an example, the maximum accuracy of the visual tracking system used by the authors is 0.01mm.

It is important to note that the authors had no methods for assessing thermal damage to the facial nerve. This inability to assess thermal damage is echoed in other mastoidectomy research papers.

Paper 3: "A Neuromonitoring Approach to Facial Nerve Preservation During Image-guided Robotic Cochlear Implantation."

Introduction:

Various computer-aided and robot-assisted techniques have been evaluated to improve mastoietomies, and have led to sub-millimeter drilling accuracy for installing cochlear implants. A minimally invasive approach drills a tunnel directly to the cochlea, with the tool following a planned path. Such procedures bring the drill very close the facial nerve, risking mechanical or thermal injury. Unfortunately, current electromyogram nerve monitors aren't reliable enough to ensure patient safety in these surgeries. Other researchers have suggested insulating the electrodes to prevent current shunting via fluids.

Two designs for stimulating electrodes are discussed. The monopolar tools are very sensitive, but don't have lateral specificity. They may detect the facial nerve at greater ranges, but the range is less specific. In contrast, bipolar tools are less sensitive, but are more spatially selective. These tools would consistently detect the facial nerve, but only when it's nearby. The authors believe an optimal solution exists, and test a multipolar probe with varying currents and stimulus durations.

Methods:

A custom multi-electrode probe is used, capable of monopolar and bipolar modes. The cone shaped tip is the cathode, while three rings along the tool body acted as anodes. These rings allowed for 3 bipolar settings. A relay was built between the four electrodes, and connected to a stimulator and an amplifier. This allowed the probe to switch between its various settings. Five sheep were used in the experiments, with approval from the appropriate review board. The subjects were desensitized and put under general anesthesia intravenously, and maintained with vaporized anesthetic. Desensitization was done with diazepam and butorphanol, anesthesia was induced with thiopental, and maintained with isoflurane.

The surgical site near the auditory canal was prepared with 4 titanium screws for registration. Planned tool trajectories were planned using CT scans using software. Three sets of parallel paths were prepared, running 0.5mm, 0.25mm, and 0.0mm next to the facial nerve, per sheep. For each trajectory, 4 reference points were defined on each trajectory, representing distances between the drill tip and the facial nerve, but the 0.5mm trajectory had 5 reference points. The sheep's head was immobilized with a clamp, and each trajectory was drilled robotically. At each reference points along a trajectory, the drill was removed and the probe was inserted for testing.

Subdermal electromyogram electrodes were placed on the Orbicularis Oris and Oculi muscles, with a ground electrode on the nose. A monopolar stimulation-return electrode was placed contralateral to the site of surgery. The EMG amplifier had a gain of 500, the impedance amplifier had a gain of 1. Frequency bandwidths were 0.01 to 5.0 kHz. Probe position was tracked with a visual tracking system.

Micro-CT was used to segment mastoids and to assess the spatial distance between reference points and the facial nerve. Distances were categorized as safe, high risk, lateral collision, and lastly frontal collision, with thresholds of 0.5mm, 0.1mm, and 0.0mm.

Seven stimulus intensities were tested, and positive and negative detection rates were recorded at 0.1mm increments from the facial nerve. If a probe ever made frontal contact with a facial nerve, the temple was examined to assess the extent of injury.

Results:

42 tunnels were drilled into 5 sheep, but 12 tunnels had to be excluded due to an inability to determine facial nerve location from CT scans. An additional tunnel was excluded due to high electrode-tissue impedance. 15 didn't collide with the facial nerve, 8 were at a safe distance, 7 were at a risky distance, and were deemed to have collided with the facial nerve. 4 were lateral collisions, 10 were frontal collisions. Stimulus intensity and facial nerve distance were correlated only when the shortest distance between the tool tip and facial nerve were less than 0.1mm. The sensitivity and specificity of facial nerve detection are summarized in the figure:

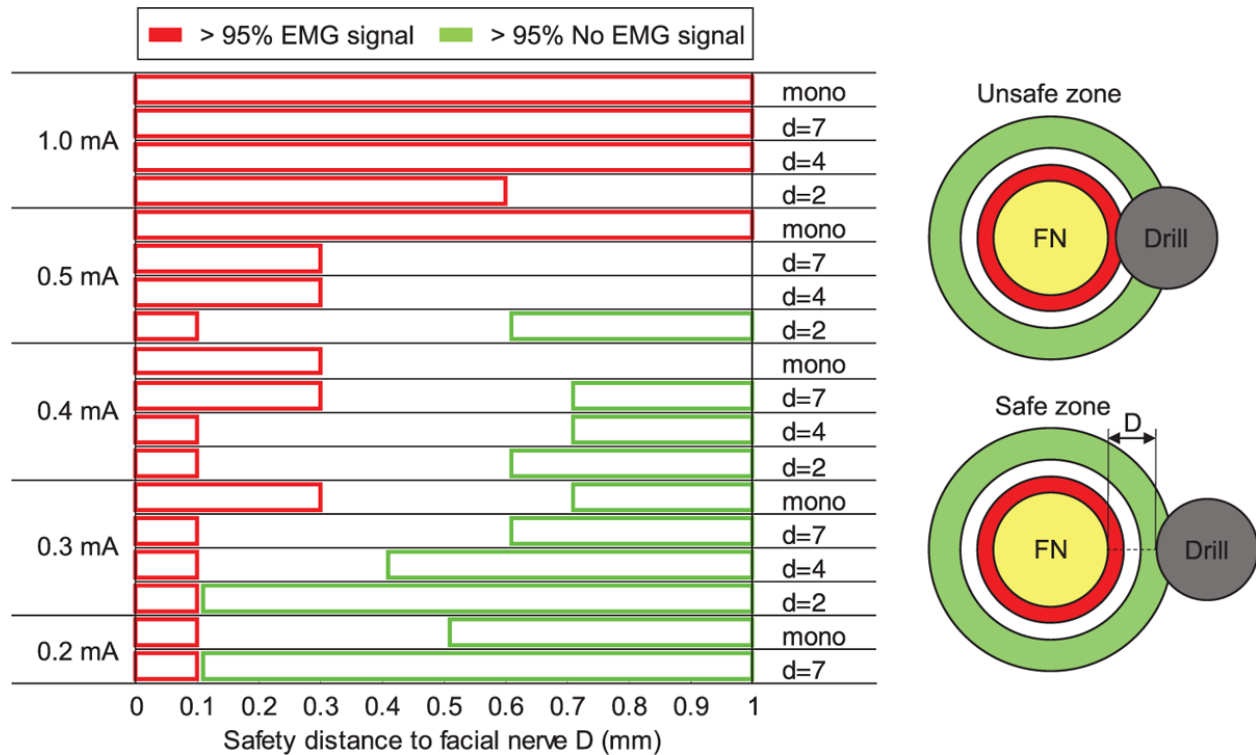


Figure 3: Facial nerve detection intervals, sensitivity, and specificity are shown. High specificity is demonstrated only in 2 cases. Taken from "A Neuromonitoring Approach to Facial Nerve Preservation During Image-guided Robotic Cochlear Implantation"

Discussion:

Patient-specific anatomical differences may cause different performance of the probe in clinical applications. Nonetheless, the system may still serve as a good binary indicator of proximity to the facial nerve, with low stimulation intensity (0.3 – 0.2 mA), and a detection range of 0.1mm. Examination of damaged facial nerves reveal that even if superficial damage to the facial nerve is dealt, immediate corrective action can prevent axonal damage of the nerve. As confirmed by previous studies, a monopolar probe with 1.0 mA current can detect the facial nerve at a distance of 1mm.

It's noted that while the bipolar probes may detect the facial nerve at a distance of 0.1mm, and immediate action can prevent mechanical damage, thermal damage may still result in severe injury.

Review:

As mentioned in the previous paper, assessing the effects of thermal damage is difficult for researchers. Nonetheless the paper confirms the effectiveness of a previous probe design. The monopolar probe at 1.0 mA current can detect the facial nerve within 1.0mm reliably. Using the paper's criteria, where a distance greater than 0.5mm is considered safe, this is a good design for a probe. The author's assessment of facial nerve damage during collisions revealed that superficial damage to the facial nerve may not be catastrophic. Surgeons using the effective bipolar designs may still retract their tools and prevent further harm, yet it's still unknown whether the nerve has been destroyed thermally.

An effective neuromonitor probe would be invaluable for mastoidectomies, so long as the coolant used in drilling doesn't interfere with its function. Given the importance of avoiding facial nerve damage, such a tool would become indispensable for ensuring the safety of the patient.

A human study would be necessary to have an accurate assessment of the probe's capabilities, because the authors acknowledge that sheep mastoids lack air cells. This would be a large problem for surgeons performing mastoidectomies to treat mastoiditis, since the conducting properties of the air cells may not be the same as more solid bone. In this case, sheep anatomy is not a good representation of human anatomy.

Conclusion:

The iterative designing of the microsurgical robot is a model for our project, now that we're on our third iteration of our mastoid phantom. Designing a new tool requires multiple attempts in order to refine its qualities as well as matching it with the intent of the project. The first iteration of the microsurgical robot is a good example of the concept of the minimal viable product. The minimum viable product is a design which satisfies core requirements, with no additional features. Next iterations would build upon this in order to produce more sophisticated designs.

The design process of our phantom reflects this process. The first iteration was a minimal viable product, a 3D printed phantom containing fiducials for registration. However, this first iteration also contained landmarks to assist surgeons in locating the facial nerve. The second iteration included a differently colored diseased layer, as well as introducing a non-drillable outer frame. Our current third iteration uses the reusable frame, but now includes wax to shorten production time.

The other two papers can demonstrate how the project may grow if continued. The effectiveness assessment can be improved using the ideas from the first revision surgery paper. It identified complete air cell removal alongside healthy tissue alterations to help prevent the need for additional surgery. The assessment can be expanded to include proper alteration to healthy tissue, using the criteria given in the paper.

The neuromonitor probe paper may inspire another drilling assessment study, where neuromonitors are utilized rather than robotic assistance. A study could be developed comparing the safety of a mastoidectomy using a normal drill, and a modified drill fitted with neuro-monitoring electrodes. The monopolar and bipolar designs could be evaluated against each other, and the control drill.

None of the above papers can accurately assess the role of thermal damage in mastoidectomies. This is one avenue to expand the project, and has been discussed with our medical mentor Dr. Stewart. Thermocouples may be attached to the drill to measure temperature. However, such an assessment is not currently possible with our constraints, and will be shelved until additional time and resources become available.

References

- [1] Vianna, Melissa, Meredith Adams, Patricia Schachern, Paulo Roberto Lazarini, Michael Mauro Paparella, and Sebahattin Cureoglu. "Differences in the Diameter of Facial Nerve and Facial Canal in Bell's Palsy - A 3-Dimensional Temporal Bone Study." *Otology & Neurotology* 35.3 (2014): 514-18. Web.
- [2] Olds, Kevin. *Robotic Assistant Systems for Otolaryngology-Head and Neck Surgery*. Thesis. Thesis / Dissertation ETD, n.d. N.p.: n.p., n.d. Print.
- [3] Ryu, Nam-Gyu, and Jin Kim. "How to Avoid Facial Nerve Injury in Mastoidectomy?" *Journal of Audiology & Otology* 20.2 (2016): 68. Web.
- [4] Communications. "Cholesteatoma." *American Academy of Otolaryngology-Head and Neck Surgery*. American Academy of Otolaryngology — Head and Neck Surgery, 04 Apr. 2017. Web. 20 Apr. 2017.