

Image-Guided Mastoidectomy with a Cooperatively Controlled ENT Microsurgery Robot

Christopher R. Razavi, MD¹, Paul R. Wilkening, MS²,
 Rui Yin², Samuel R. Barber, MD³, Russell H. Taylor, PhD²,
 John P. Carey, MD¹, and Francis X. Creighton, MD¹

Otolaryngology—
 Head and Neck Surgery
 2019, Vol. 161(5) 852–855
 © American Academy of
 Otolaryngology–Head and Neck
 Surgery Foundation 2019
 Reprints and permission:
sagepub.com/journalsPermissions.nav
 DOI: 10.1177/0194599819861526
<http://otojournal.org>



Sponsorships or competing interests that may be relevant to content are disclosed at the end of this article.

Abstract

Mastoidectomy is a common surgical procedure within otology. Despite being inherently well suited for implementation of robotic assistance, there are no commercially available robotic systems that have demonstrated utility in aiding with this procedure. This article describes a robotic technique for image-guided mastoidectomy with an experimental cooperatively controlled robotic system developed for use within otolaryngology–head and neck surgery. It has the ability to facilitate enhanced operative precision with dampening of tremor in simulated surgical tasks. Its kinematic design is such that the location of the attached surgical instrument is known with a high degree of fidelity at all times. This facilitates image registration and subsequent definition of virtual fixtures, which demarcate surgical workspace boundaries and prevent motion into undesired areas. In this preliminary feasibility study, we demonstrate the clinical utility of this system to facilitate performance of a cortical mastoidectomy by a novice surgeon in 5 identical temporal bone models with a mean time of 221 ± 35 seconds.

Keywords

robotic surgery, robotic mastoidectomy, otology, image guidance

Received November 30, 2018; accepted June 14, 2019.

Robotic surgical systems have been cited as having the potential to reduce complications and morbidity given their ability to perform accurate and repeatable motions with the elimination of tremor.^{1,2} Mastoidectomy is a procedure that would seem to lend itself to robotic assistance; the operative field consists of rigid bone in a fixed orientation that facilitates image guidance.³ Despite this, no commercially available robotic technology has demonstrated clinical utility in this procedure.

Although there are feasibility studies describing the use of novel robots in performing mastoidectomy, many of these have autonomous designs.^{3–10} As autonomous robotic systems operate independently, they require knowledge of burr selection and of the appropriate force required to safely perform various portions of the procedure.¹⁰ Due to variability in mastoid aeration, there is a subsequent patient and spatially dependent variation in bone density.¹¹ Accordingly, these systems require patient-specific force/path modeling to maximize operative efficiency and safety. Conversely, cooperatively controlled robots, in which the user and robot manipulate the surgical drill together, obviate the above requirements. The user can make determinations regarding burr selection and drill angle/force in the typical fashion, while still appreciating benefits of tremor elimination, enhanced precision, and image guidance that the robot may facilitate.

We have developed an experimental cooperatively controlled robot for ear, nose, and throat (ENT) microsurgery and have demonstrated its use in simulated microlaryngeal, microvascular, and otologic surgical tasks due to its ability to eliminate tremor, enhance precision, and have accurate knowledge of tool position in 3-dimensional space.^{12–15} Here we describe its capability to incorporate image-based virtual fixtures facilitating cortical mastoidectomy by a novice surgeon.

Methods

The robotic platform used in this study is a cooperative-control robot consisting of a gantry arm with 5 actuated

¹Department of Otolaryngology–Head & Neck Surgery, Johns Hopkins University School of Medicine, Baltimore, Maryland, USA

²Laboratory for Computational Sensing and Robotics, Johns Hopkins University, Baltimore, Maryland, USA

³Department of Otolaryngology–Head and Neck Surgery, University of Arizona College of Medicine, Tucson, Arizona, USA

This article was presented at the AAO-HNSF 2018 Annual Meeting & OTO Experience; October 7–10, 2018; Atlanta, Georgia.

Corresponding Author:

Christopher R. Razavi, MD, Department of Otolaryngology–Head and Neck Surgery, Johns Hopkins Medical Institute, 601 N. Caroline Street, 6th Floor, Baltimore, MD 21287, USA.

Email: crazavi1@jhmi.edu




Figure 1. The third-generation research version of the Robotic ENT Microsurgery System. The 5 degrees of actuated freedom are labeled, while a custom-built pointer tool is attached to the gantry arm.

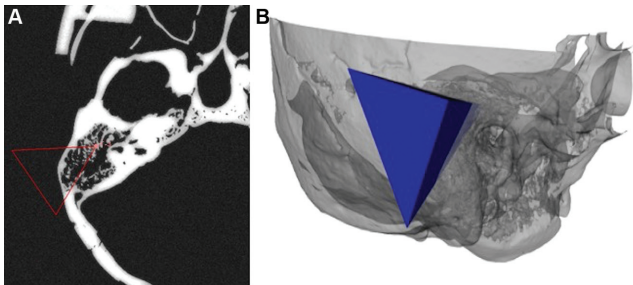


Figure 2. Representation of the allowable working space as seen on axial cut computed tomography (A) and 3-dimensional reconstruction (B) of the imaging.

degrees of freedom (**Figure 1**). Conventional surgical instruments can be fit with adaptors to articulate with the device. For this study, a Midas Rex Legend drill (Medtronic, Minneapolis, Minnesota) with a 4-mm cutting burr was used. The iteration of the technology used was an updated prototype of the robotic platform that we have previously described at length.^{12,13,16-19} In summary, its design allows for the user to manipulate the attached instrument with dampening of tremor and heightened precision. The position of the gantry arm and, therefore, attached instrument, is known with a high degree of fidelity. Therefore, after image registration, boundaries of allowable motion (virtual fixtures) can be enforced. When these virtual fixtures are activated, the instrument affixed to the robot is adherent to spatial motion

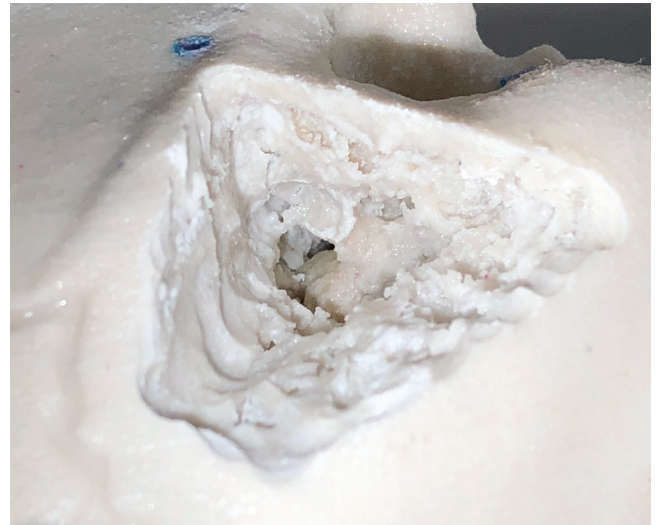

Figure 3. Representative image of a specimen after drilling has been completed. The antrum has been entered, and the horizontal canal can be visualized.

constraints, where it is permitted to move freely within the described volume, but motion outside is forbidden.²⁰

A right temporal bone model (Phacon, Leipzig, Germany) was used as the surgical phantom and registered to the robot using accompanying imaging. Using 3D Slicer (open source, <https://www.slicer.org>),²¹ 3 intersecting planes were created within the imaging so that the resultant geometry approximated the volume of bone removed during a cortical mastoidectomy (**Figure 2**). After registration and virtual fixture activation, a software engineer was instructed to drill away material within the allowable working space. He received no intraoperative coaching, while indicating procedure completion when the drill could no longer reach areas of intact phantom material. This task was repeated 5 times (see the supplemental video in the online version of the article). Outcomes included time to completion and procedural success, which was defined as entrance into the antrum with preservation of the incus, horizontal canal, facial nerve, tegmen, sigmoid sinus, posterior fossa dura, and external auditory canal. Procedural success was evaluated via specimen review by a fellowship-trained neurotologist (J.P.C.) who was not present during the time of drilling. Johns Hopkins University Institutional Review Board Approval was obtained.

Results

Procedural success was 100% (5/5), with entrance into the antrum and protection of the aforementioned structures in all cases (**Figure 3**). The task was completed in an average of 221 ± 35 seconds. There was a trend toward more expeditious completion of the procedure with sequential trial times of 267, 249, 225, 177, and 185 seconds.

Discussion

The robot facilitated cortical mastoidectomy safely in 100% of cases in this proof-of-concept study. Given the excellent

expected outcomes and low complication rate with mastoid surgery, robotic systems in this space must be safe but also provide additional benefits in our value-based health care system.³ One such potential avenue is in reducing operative time. The 221-second mean procedure time in our series is in stark contrast to reported drilling times of 5400 seconds for a similar task by an autonomously operated robotic mastoidectomy system.³ These preliminary results suggest that the cooperative control design of the robot may reduce procedure time in comparison to autonomous systems and, potentially, freehand techniques.

Prior literature describing robotic mastoidectomy has noted that these devices still require the same level of neurotologic expertise as the open approach to safely and effectively function.⁸ This is despite the autonomous design of many of these platforms. In contrast, we demonstrated that robot-assisted mastoidectomy could be safely performed by a novice surgeon. Although this was in a simulated surgical task and required expertise in operative planning, this suggests the robot may provide value to the less experienced surgeon. Further studies are needed to elucidate this and to examine whether experienced neurotologists may derive utility when performing more complex surgical tasks.

Conclusions

The robot safely facilitated cortical mastoidectomy by an engineer with no prior surgical experience. The cooperative-control design provides many potential benefits over previously described autonomous devices. These include decreased drill time and utility to less experienced surgeons. Future cadaveric studies evaluating performance with more complex dissections are needed to delineate its ultimate clinical utility.

Author Contributions

Christopher R. Razavi, conception/design, data acquisition, data analysis, manuscript drafting, final approval; **Paul R. Wilkening**, conception/design, data acquisition, manuscript drafting, final approval; **Rui Yin**, conception/design, data acquisition, manuscript drafting, final approval; **Samuel R. Barber**, conception/design, data acquisition, manuscript drafting, final approval; **Russell H. Taylor**, conception/design, data acquisition, manuscript drafting, final approval; **John P. Carey**, conception/design, data acquisition, manuscript drafting, final approval; **Francis X. Creighton**, conception/design, data acquisition, manuscript drafting, final approval.

Disclosures

Competing interests: Paul R. Wilkening, employee of Galen Robotics; Rui Yin, intern at Galen Robotics; Russell H. Taylor, consultant at Galen Robotics and equity holder in Galen Robotics.

Sponsorships: None.

Funding source: NIH T32 Training Grant: T32 DC000027: this funding source did not have a role in study design/conduct, data review, analysis, or writing/approval of the manuscript.

Supplemental Material

Additional supporting information is available in the online version of the article.

References

1. Taylor R, Jensen P, Whitcomb L, et al. A steady-hand robotic system for microsurgical augmentation. *Int J Robot Res*. 1999; 18:1201-1210.
2. Taylor RH, Stoianovici D. Medical robotics in computer-integrated surgery. *IEEE Trans Robot Autom*. 2003;19:765-781.
3. Danilchenko A, Balachandran R, Toennies JL, et al. Robotic mastoidectomy. *Otol Neurotol*. 2011;32:11-16.
4. Xia T, Baird C, Jallo G, et al. An integrated system for planning, navigation and robotic assistance for skull base surgery. *Int J Med Robot*. 2008;4:321-330.
5. Bell B, Stieger C, Gerber N, et al. A self-developed and constructed robot for minimally invasive cochlear implantation. *Acta Otolaryngol*. 2012;132:355-360.
6. Kratchman LB, Blachon GS, Withrow TJ, Balachandran R, Labadie RF, Webster RJ III. Design of a bone-attached parallel robot for percutaneous cochlear implantation. *IEEE Trans Biomed Eng*. 2011;58:2904-2910.
7. Dillon NP, Kratchman LB, Dietrich MS, Labadie RF, Webster RJ III, Withrow TJ. An experimental evaluation of the force requirements for robotic mastoidectomy. *Otol Neurotol*. 2013; 34:e93-e102.
8. Labadie RF, Balachandran R, Noble JH, et al. Minimally invasive image-guided cochlear implantation surgery: first report of clinical implementation. *Laryngoscope*. 2014;124:1915-1922.
9. Dillon NP, Balachandran R, Siebold MA, Webster RJ III, Wanna GB, Labadie RF. Cadaveric testing of robot-assisted access to the internal auditory canal for vestibular schwannoma removal. *Otol Neurotol*. 2017;38:441-447.
10. Zagzoog N, Yang VXD. State of robotic mastoidectomy: literature review. *World Neurosurg*. 2018;116:347-351.
11. Dillon NP, Fichera L, Wellborn PS, Labadie RF, Webster RJ III. Making robots mill bone more like human surgeons: using bone density and anatomic information to mill safely and efficiently. *Rep U S*. 2016;2016:1837-1843.
12. Feng AL, Razavi CR, Lakshminarayanan P, et al. The robotic ENT microsurgery system: a novel robotic platform for microvascular surgery. *Laryngoscope*. 2017;127:2495-2500.
13. Akst LM, Olds KC, Balicki M, Chalasani P, Taylor RH. Robotic microlaryngeal phonosurgery: testing of a “steady-hand” microsurgery platform. *Laryngoscope*. 2018;128:126-132.
14. Razavi CR, Creighton FX, Wilkening PR, Peine J, Taylor RH, Akst LM. Real-time robotic airway measurement: an additional benefit of a novel steady-hand robotic platform. *Laryngoscope*. 2019;129:324-329.
15. Razavi CR, Wilkening PR, Yin R, et al. Applied force during piston prosthesis placement in a 3D-printed model: freehand vs robot-assisted techniques. *Otolaryngol Head Neck Surg*. 2019;160:320-325.
16. Olds KC, Taylor RH. Steady hand micromanipulation robot. The Johns Hopkins University; US Patent 8,911,429. December 16, 2014.
17. Olds KC, Taylor RH. Steady hand micromanipulation robot. The Johns Hopkins University; US Patent 9,554,865. January 31, 2017.

18. Olds KC, Chalasani P, Pacheco-Lopez P, et al. Preliminary evaluation of a new microsurgical robotic system for head and neck surgery. *IEEE Int C Int Robot*. 2014;1276-1281.
19. Olds K. *Robotic Assistant Systems for Otolaryngology-Head and Neck Surgery* [PhD thesis]. Baltimore, MD: The Johns Hopkins University; 2015.
20. Li M, Ishii M, Taylor R. Spatial motion constraints using virtual fixtures generated by anatomy. *IEEE Trans Robotics*. 2007;23:4-19.
21. Fedorov A, Beichel R, Kalpathy-Cramer J, et al. 3D Slicer as an image computing platform for the Quantitative Imaging Network. *Magn Reson Imaging*. 2012;30:1323-1341.